

Recent Advances in Nuclear Cardiology

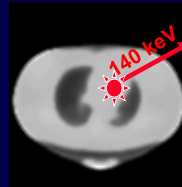
The Impact of PET Myocardial Perfusion Imaging and New Pharmacologic Stress Agents

Dennis A. Calnon, MD, FACC, FASE, FASNC

*Director, Nuclear Cardiology,
Riverside Methodist Hospital and
MidOhio Cardiology and Vascular Consultants*

SPECT MPI

(Single-Photon Emission Computed Tomography Myocardial Perfusion Imaging)



- Widely available
- ^{201}Tl Thallium, $^{99\text{m}}\text{Tc}$ -sestamibi, or $^{99\text{m}}\text{Tc}$ -tetrofosmin
- Gated images allow for LVEF calculation
- Prognostic value well established

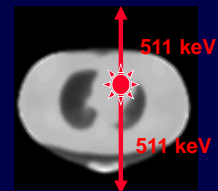
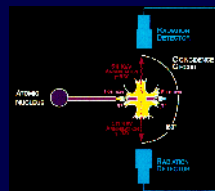
Limitations of SPECT MPI

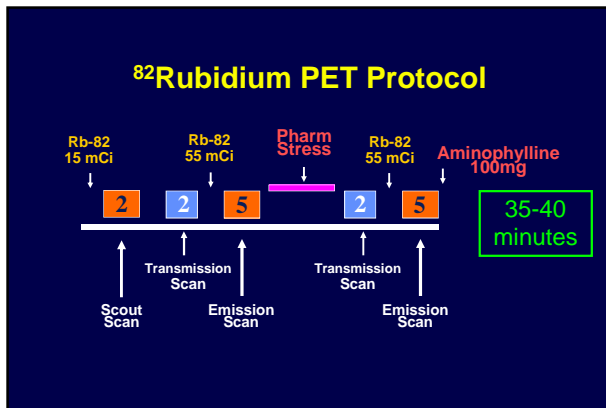
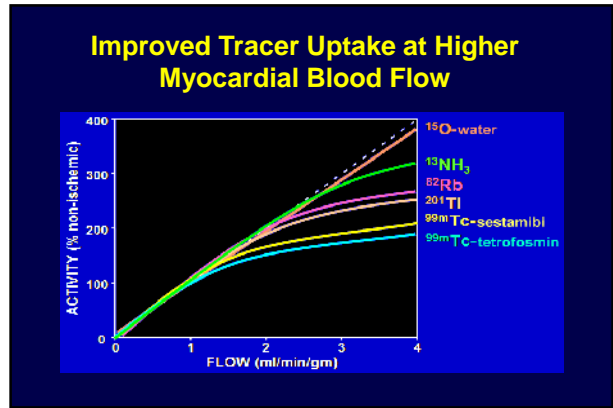
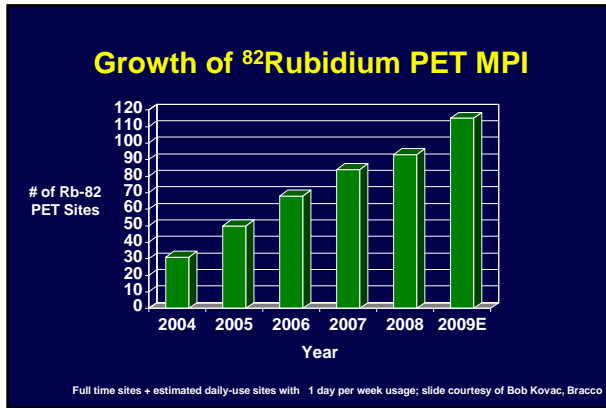


1. Perfusion tracers underestimate severity of CAD
2. Imaging protocols are inefficient
3. Attenuation artifacts are common
4. GI tracer interference is problematic
5. Interpretation confidence is low

PET MPI

(Positron Emission Computed Tomography Myocardial Perfusion Imaging)






Patient Selection for PET MPI

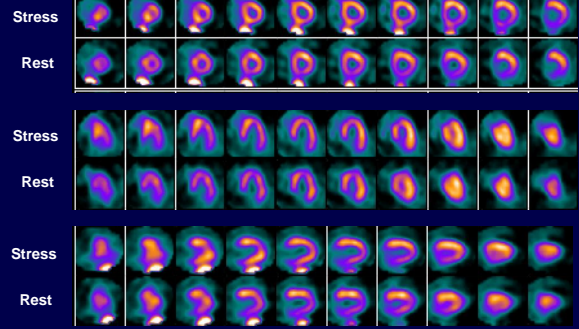
1. Prior equivocal SPECT MPI

69 y.o. woman with PCI of mid LAD 3 yrs ago, referred for ^{99m}Tc-MIBI SPECT MPI for symptoms of dyspnea and chest pressure.

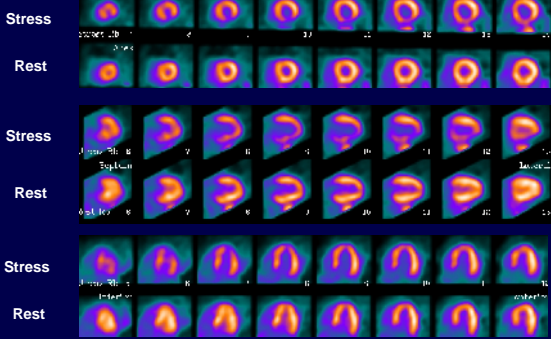


Ht: 5' 5"
 Wt: 222 lbs
 BMI: 37
 Bra: 40 D
 Adenosine
 No exercise

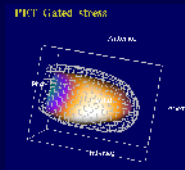
^{99m}Tc-Sestamibi SPECT MPI



⁸²Rubidium PET MPI

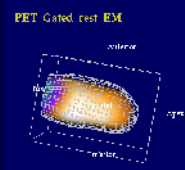


Peak Stress



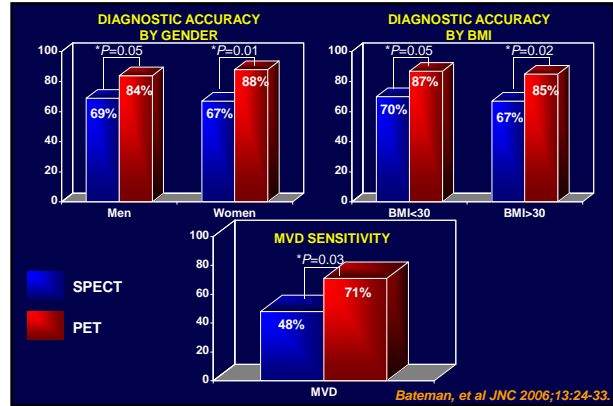
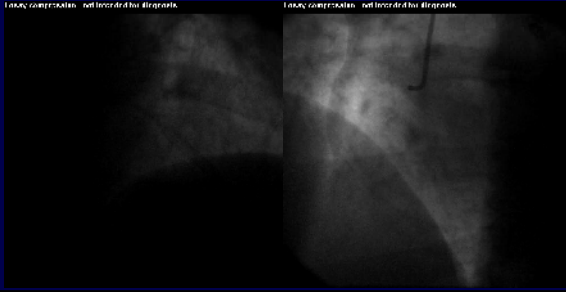
EF = 62%

Resting



EF = 73%

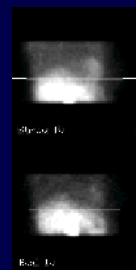
Coronary Angiography



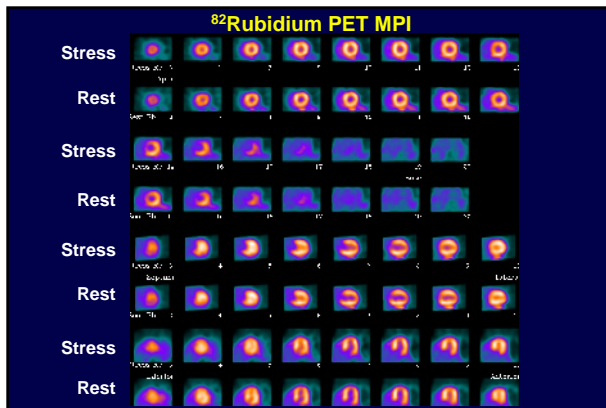
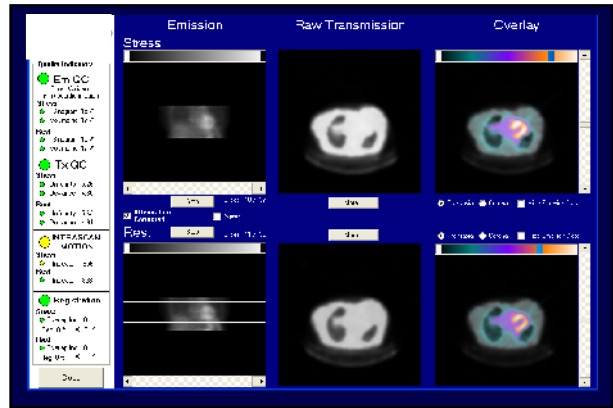
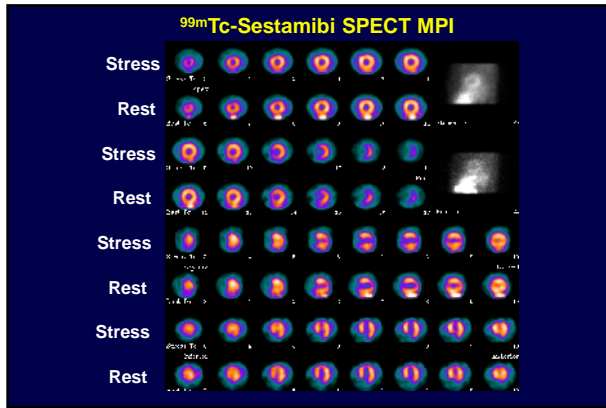
Patient Selection for PET MPI

1. Prior equivocal SPECT MPI
2. Patients likely to have equivocal SPECT MPI
 - a. Pharmacologic stress (especially if LBBB, ventricular pacer, or unable to use low-level exercise)
 - b. Body habitus likely to result in attenuation artifact (obese, women with dense breasts or implants)

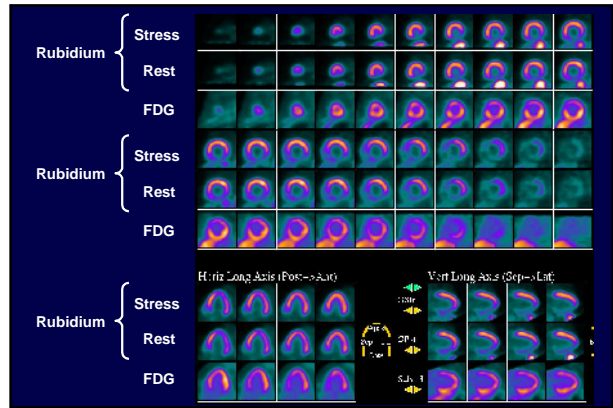
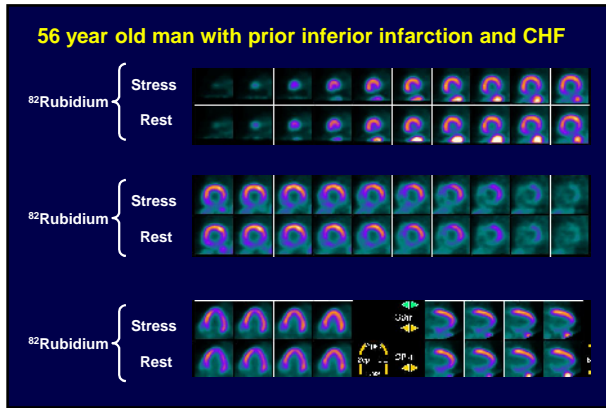
60 year old woman with atypical chest pain History of breast cancer with left breast reconstruction



Ht: 5' 7"
Wt: 155 lbs
BMI: 24.3



- ### Patient Selection for PET
1. Prior equivocal SPECT MPI
 2. Patients likely to have equivocal SPECT MPI
 - a. Pharmacologic stress (especially if LBBB, ventricular pacer, or unable to use low-level exercise)
 - b. Body habitus likely to result in attenuation artifact (obese, women with dense breasts or implants)
 3. Myocardial viability assessment



Emerging Clinical Applications

1. Absolute quantification of myocardial blood flow

Measurement of Myocardial Blood Flow

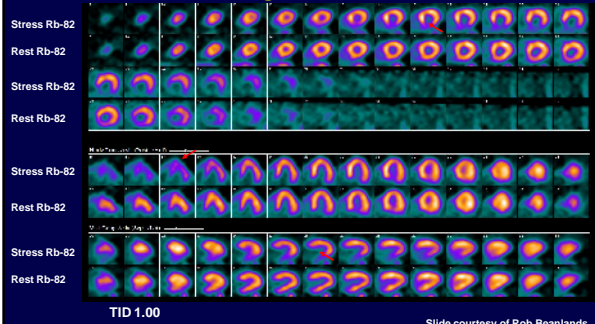
Relative ———→ compared to “most normal” region

Absolute ———→ ml/min/gm of myocardium

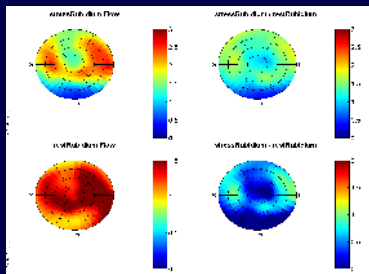
Clinical Value of Measuring Absolute Myocardial Blood Flow

1. Verify efficacy of pharmacological vasodilation
2. Measurement of myocardial flow reserve
3. Detection of endothelial dysfunction and/or microvascular disease (abnormal myocardial flow reserve in absence of epicardial coronary stenosis)
4. Detection of "balanced ischemia"

73 yr old man with HTN, PAD, CRF, presented with increased angina for several months



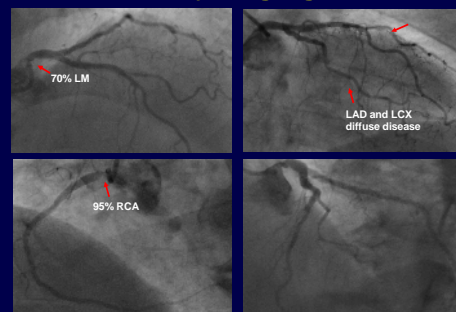
Quantitative Perfusion



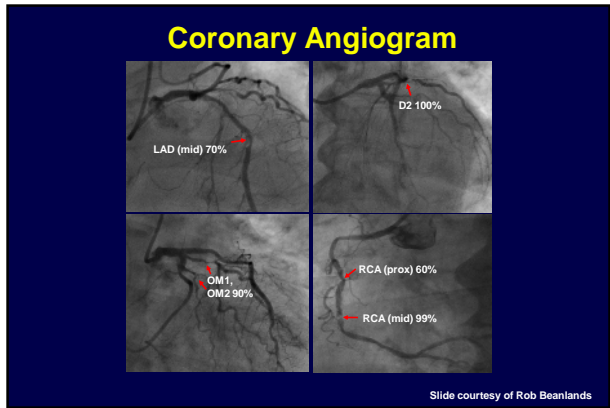
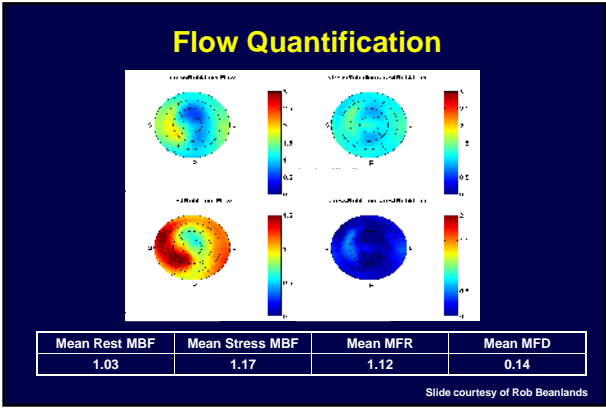
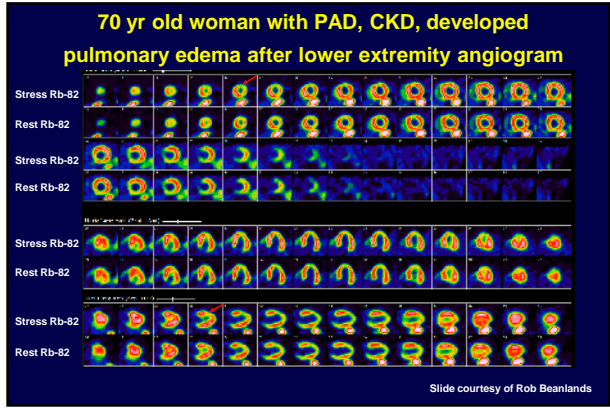
Mean Rest MBF	Mean Stress MBF	Mean MFR	Mean MFD
1.38	1.76	1.26	0.38

Slide courtesy of Rob Beanlands

Coronary Angiogram

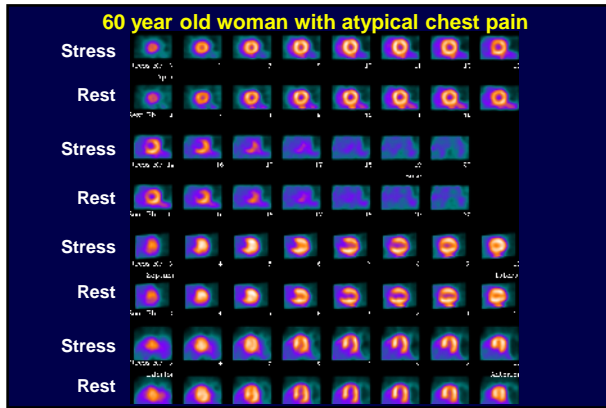

Slide courtesy of Rob Beanlands



Emerging Clinical Applications

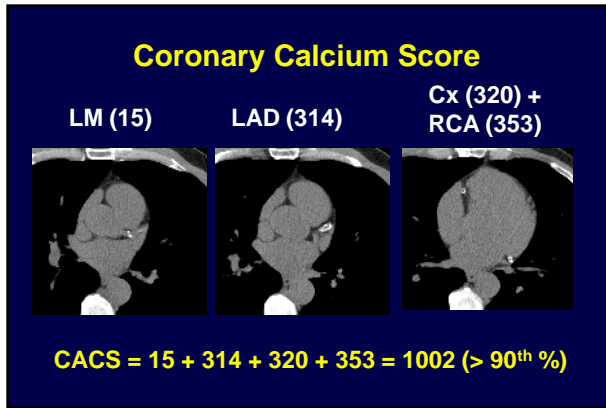
1. Absolute quantification of myocardial blood flow
2. Combined perfusion and atherosclerosis imaging



Clinical Questions

Would she benefit from coronary revascularization? **No**

Would she benefit from aggressive risk factor modification? **We don't know**

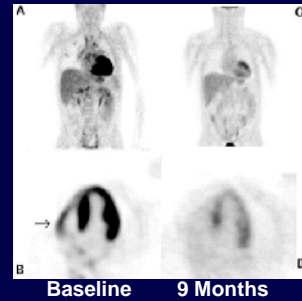


MPI	CT
Physiology	Anatomy
Short-term (2 y) risk	Long-term (10 y) risk
Revascularization?	Secondary Prevention?

Emerging Clinical Applications

1. Absolute quantification of myocardial blood flow
2. Combined perfusion and atherosclerosis imaging
3. Cardiac sarcoidosis

Diffuse Myocardial Inflammation in Cardiac Sarcoidosis Demonstrated by ^{18}F -FDG

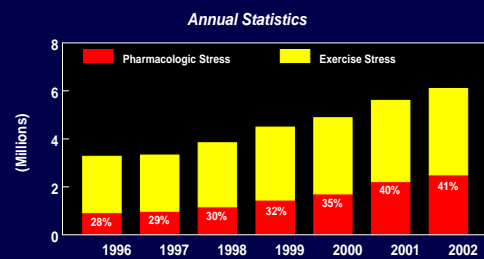


Baseline 9 Months

Danielle Casset-Senon, et al, J Nucl Cardiol 2008;15(2):282-285.

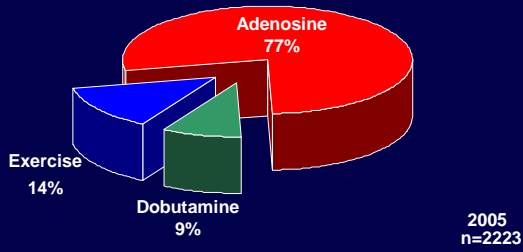
New Pharmacologic Stress Agents

Increasing Use of Pharmacologic Stress



Source: AMR Monthly Monitor

Inpatients at Riverside Methodist Hospital



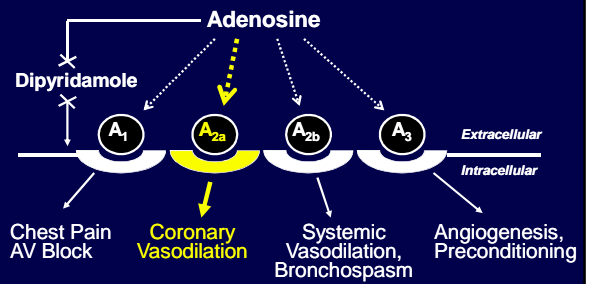
Limitations of Available Pharmacologic Stress Agents

1. Frequent side-effects
2. Duration of action is too long (dipyridamole) or too short (adenosine)
3. Contraindicated with reactive airways disease
4. Intravenous infusion pump required
5. Need to abstain from caffeine

Side Effects

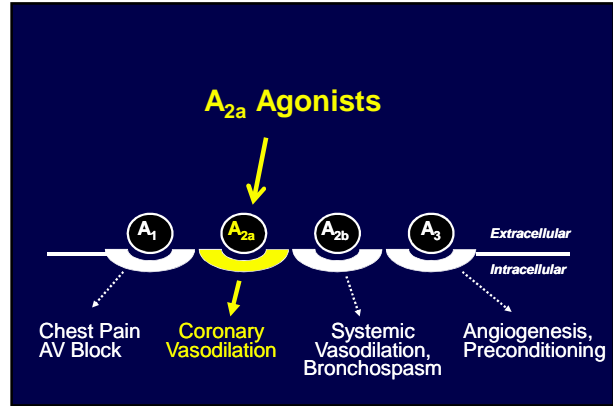
Side effect (%)	Adenosine n=9,256	Dipyridamole n=3911	Dobutamine n=1012
Flushing	37	3	10
Dyspnea	35	3	12
Chest pain	35	20	31
Headache	14	12	14
Lightheaded	9	12	NR
AV block	8	0.1	0
Arrhythmia	3	5	4

Mechanism of Action

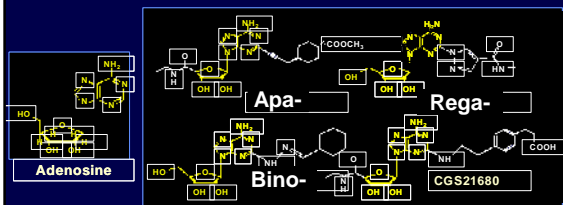


The Ideal Pharmacologic Stress Agent

Ideal Features	Benefits
Selectivity for A _{2a} receptor	Side effects
Rapid onset & termination of action	Hyperemia only during radiotracer uptake
Bolus administration	Ease of use, costs
No bronchospasm	Safe in asthma, COPD
Fixed dose	Easy, less dosing errors
No caffeine interaction	Schedule flexibility

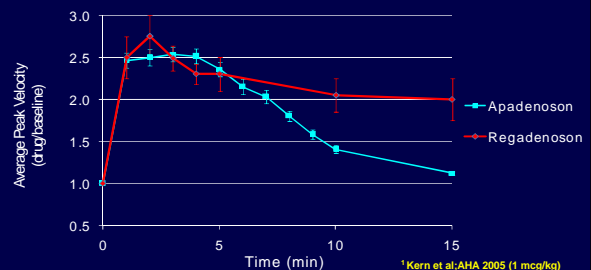


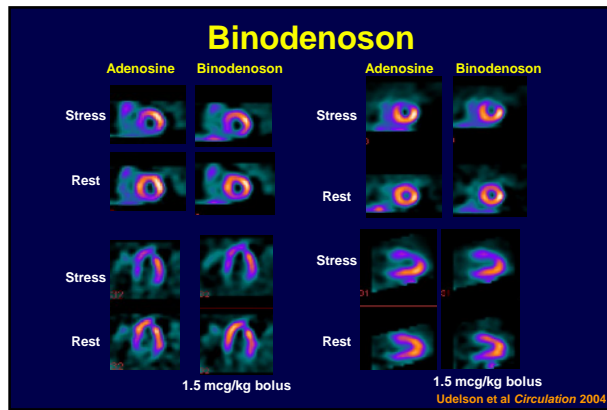
A_{2a} Receptor Agonists The “-denosons”



Slide Courtesy of David Glover, PhD

Increase in Coronary Flow Velocity with Apadenoson and Regadenoson (IV bolus)





Apadenoson

Adverse Event	Apadenoson (1µg/kg bolus)	Adenosine (140µg/kg/min)	P value
Chest pain	8 (13%)	43 (35%)	<0.05
Dyspnea	4 (7%)	40 (32%)	<0.05
Flushing	0	18 (15%)	<0.05
Headache	3 (5%)	17 (14%)	NS
Dizziness	6 (10%)	18 (15%)	NS
AV block	0	3 (2%)	NS
Any	22 (36%)	105 (85%)	<0.0001

Hendel et al. *AHA*. 2005

Frequency of AEs with A_{2A} Agonists

	<u>Binodenoson</u>	<u>Regadenoson</u>	<u>Apadenoson</u>	<u>Adenosine</u>
Dose (ug/kg)	1.5	400 ug unit dose	1	Std infusion
Any	72 (28%)	79 (1%)	36 (57%)	85
Chest Pain	45 (26%)	26 (26%)	13 (63%)	44
Dyspnea	42 (28%)	25 (39%)	7 (61%)	36
Flushing	34 (40%)	17 (29%)	0 (100%)	32
Headache	32 (19%)	28 (87%)	5 (64%)	19
Nausea	11 (10%)	6 (20%)	3 (79%)	10
AV Block	0 (100%)	2 (67%)	0 (100%)	4

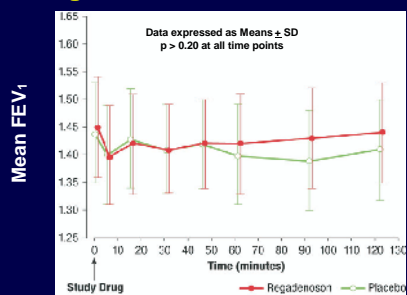
Source(s) Udelson Circ 2004 Iskandrian ASNC 2005 Hendel AHA 2005 Average of 3 Wackers ASNC 2003

Adverse Events in Patients with COPD

	<u>Regadenoson</u>	<u>Placebo</u>
Any adverse event	86%	12%
Dyspnea	61%	0
Flushing	39%	2%
Headache	35%	4%
Dizziness	27%	4%
Nausea	14%	2%
Chest discomfort	12%	0

Thomas et al. *J Nucl Cardiol* 2008;15:319-328

Changes in FEV₁ in COPD Patients



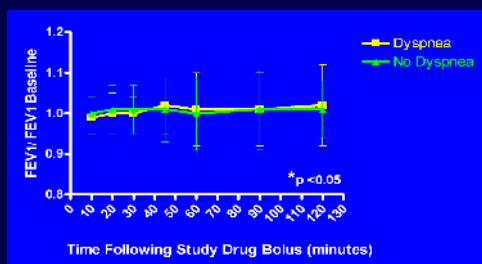
Thomas et al, J Nucl Cardiol 2008;15:319-328

Adverse Events in Patients with Asthma

	Regadenoson	Placebo
Any AE	98%	8%
Tachycardia	66%	2%
Dizziness	53%	0
Headache	45%	2%
Dyspnea	34%	0
Flushing	32%	2%
Chest discomfort	21%	2%
Nausea	19%	2%
Parestias	19%	0

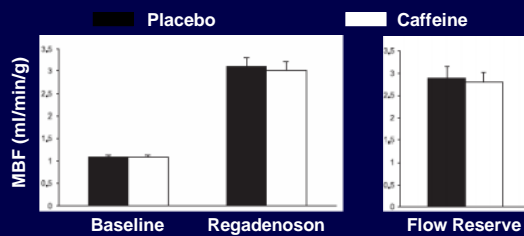
Leaker, et al, J Nucl Cardiol 2008;15:329-36

Effect of Regadenoson on FEV₁ in Asthma Subjects With and Without Dyspnea



Leaker, et al, J Nucl Cardiol 2008;15:329-36

Effect of Caffeine (200 mg) on Regadenoson-Induced Myocardial Hyperemia (n=41)



Gaemperli, et al, JACC 2008;51:328-329

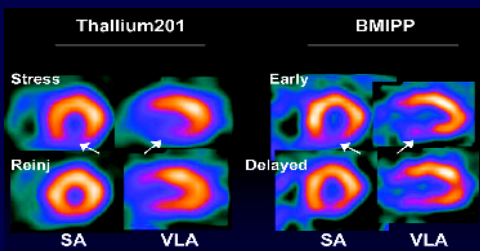
Adenosine A_{2a} Agonists

Ideal Features		A _{2a} Agonists
Selectivity for A _{2a} receptor	➡	Yes
Rapid onset & termination of action	➡	Yes
Bolus administration	➡	Yes
No bronchospasm	➡	Yes?
Fixed dose	➡	Yes
No caffeine interaction	➡	Yes?

Expanding the Boundaries of Nuclear Cardiology

“Beyond Perfusion and Function”

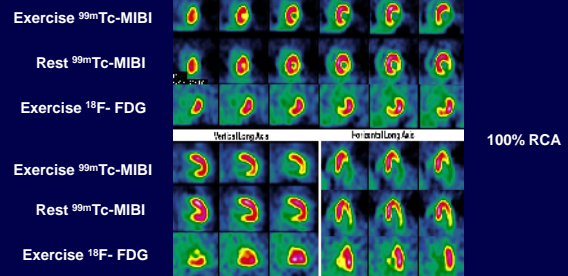
¹²³I BMIPP Imaging and “Ischemic Memory” (Prolonged Impairment of Fatty Acid Metabolism)



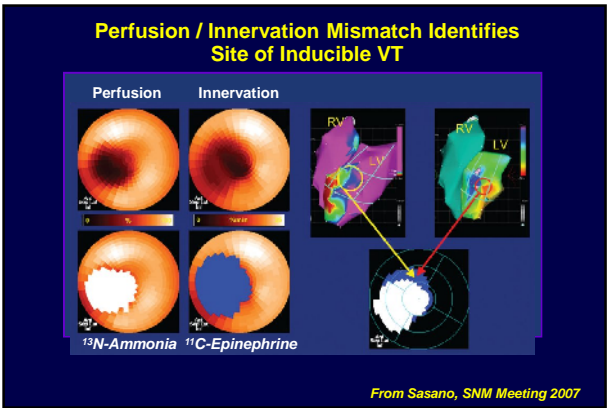
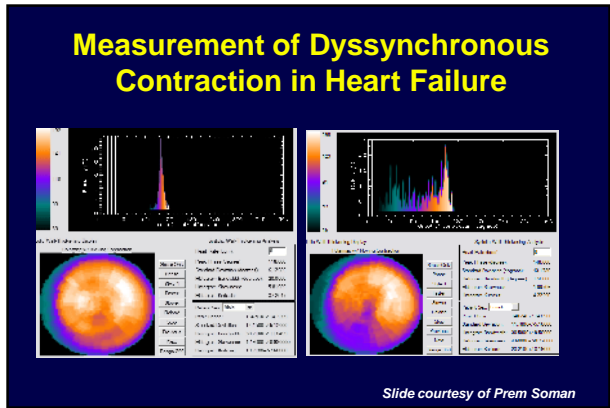
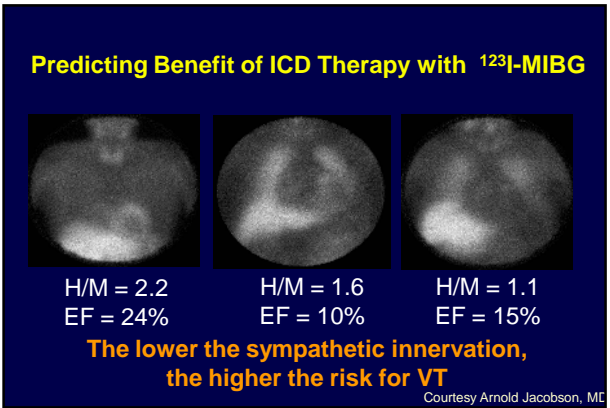
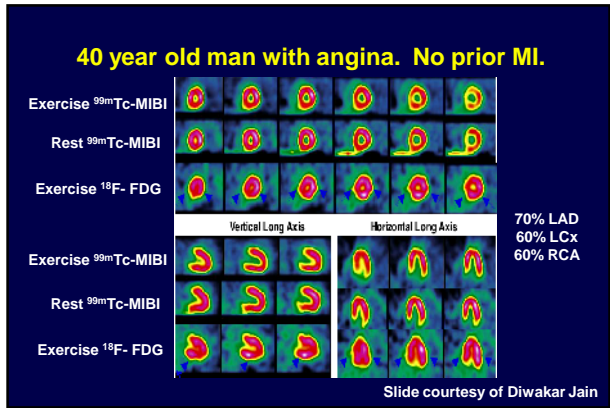
Copyright © 2005 American Heart Association

Dilsizian, V. et al. Circulation 2005;112:2169-2174

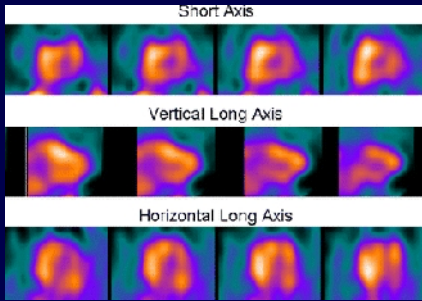
49 year old woman with angina



Slide courtesy of Diwakar Jain

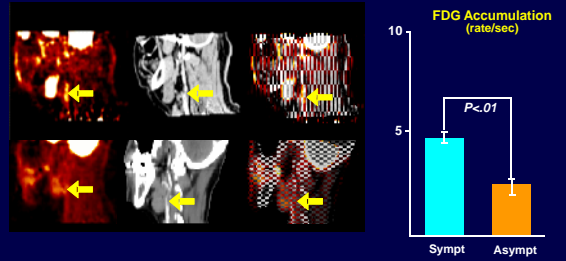


Diffuse Myocardial Apoptosis 9 Months After Heart Transplantation Demonstrated by ^{99m}Tc-Annexin V



Eur J Nucl Med Mol Imaging. 2007;34:86-98.

¹⁸F-FDG in Vulnerable Carotid Plaques



FDG = fluorodeoxyglucose; sympt = symptomatic; asympt = asymptomatic.
Reprinted with permission from Rudd JHF, Warburton EA, Fryer TD, et al. Imaging atherosclerotic plaque inflammation with [¹⁸F]fluorodeoxyglucose positron emission tomography. *Circulation*. 2002;105(23):2708-2711; Weissberg P et al. *Circulation* 2004.

Questions?
dcalnon@mocvc.com

