



The Christ Hospital

# ACC Ohio Chapter 20<sup>th</sup> Annual Meeting

Wojciech Mazur MD, FACC

Associate Professor of Clinical Medicine and Pediatrics

Medical Director Advanced Cardiac Imaging

The Heart and Vascular Center at The Christ Hospital,

Cincinnati, OH

USA



The Christ Hospital

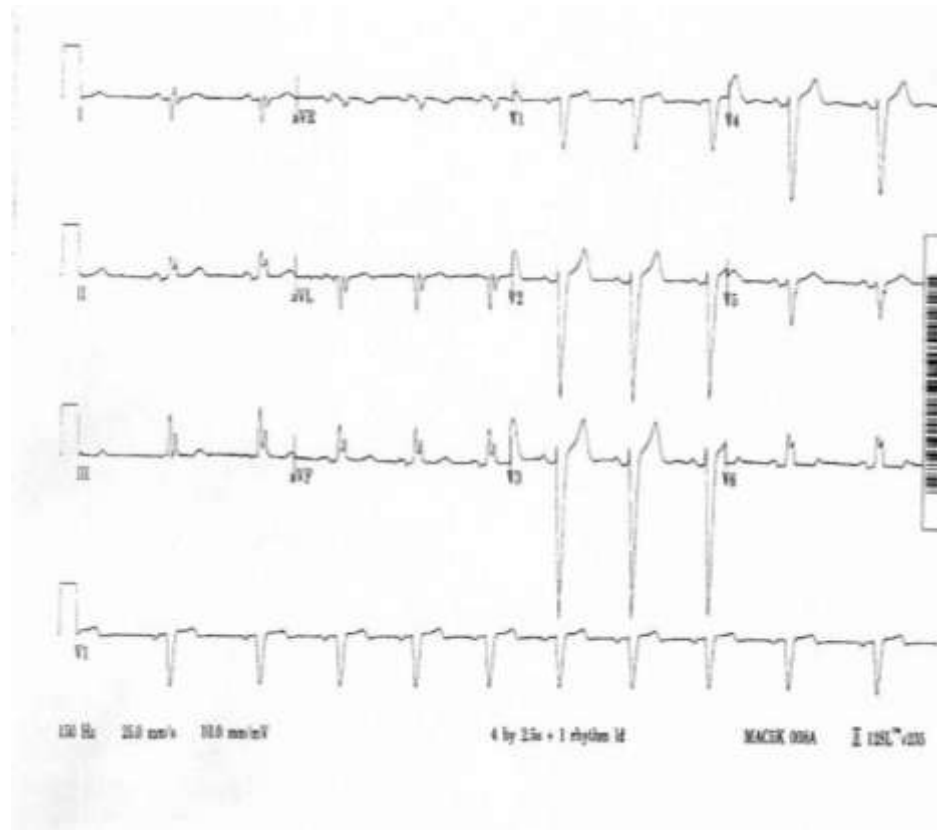
# New onset CHF in An Athlete

- 22 year old soccer player without past medical history, presented for evaluation of more than expected exertional dyspnea, during training, which gradually progressed over few months to dyspnea while climbing 2 flights of stairs
- Physical examination: 127/78, HR 78, Wt 220, H6'4"
- HEENT: unremarkable
- Chest CTA
- CV RRR, no murmur and gallops, PMI displaced inferiorly and lateral, no JVD
- Abdomen: unremarkable
- Extremity no edema





## 12 Lead ECG



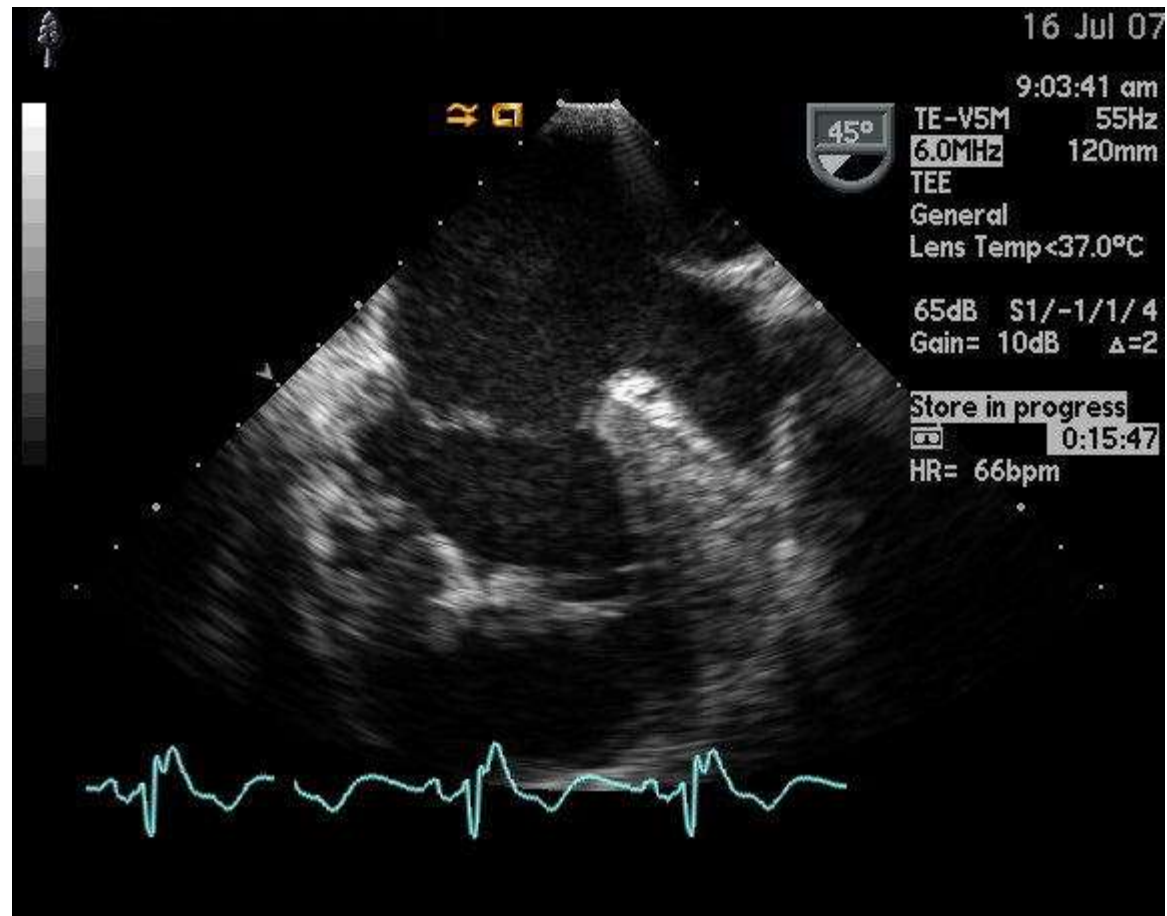


# Which test would you order next?

- A: TTE
- B: CMR
- C: Cardiac CT
- E: MUGA



# Transesophageal Echocardiogram

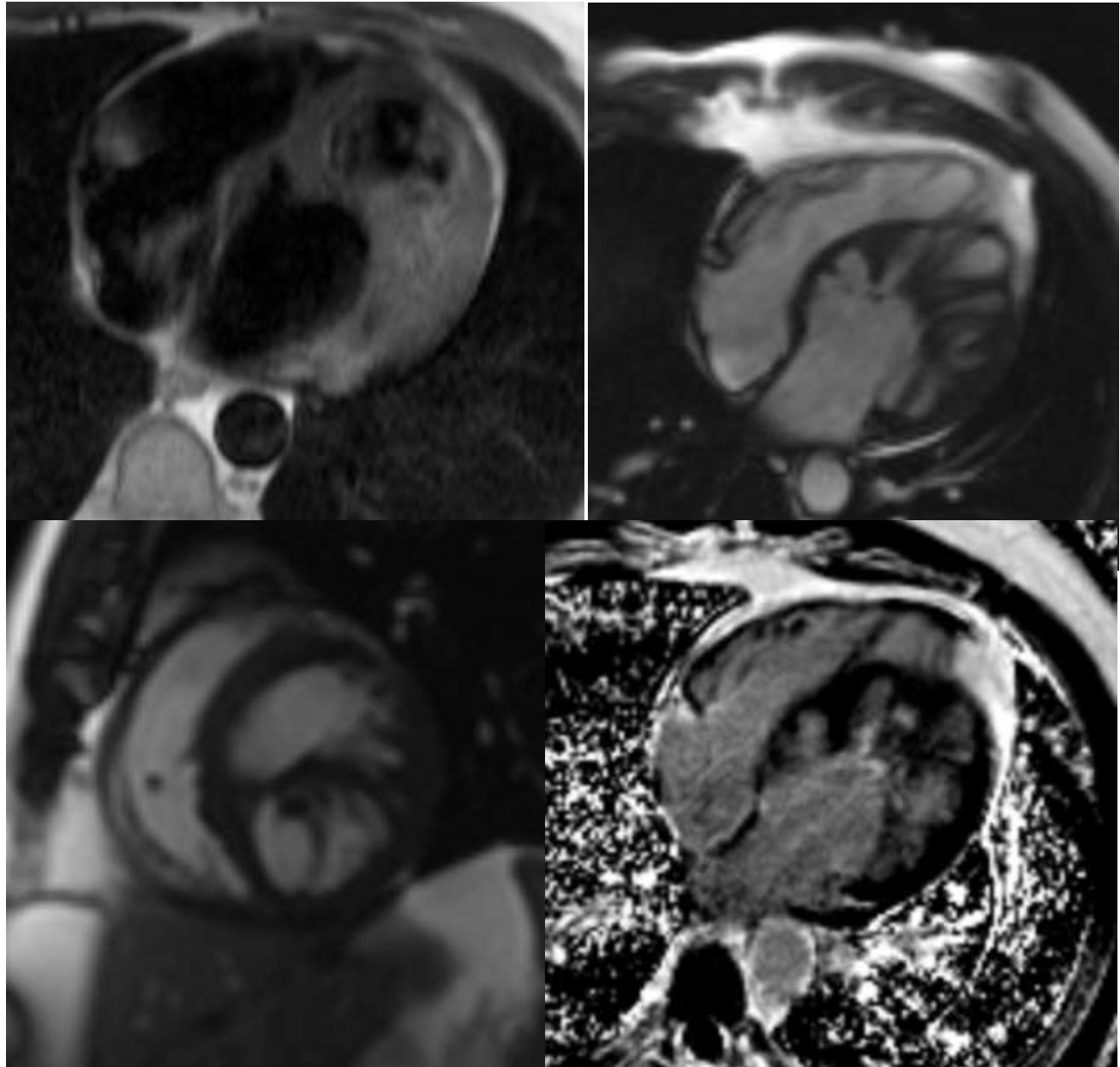




Do we really have the  
diagnosis yet?

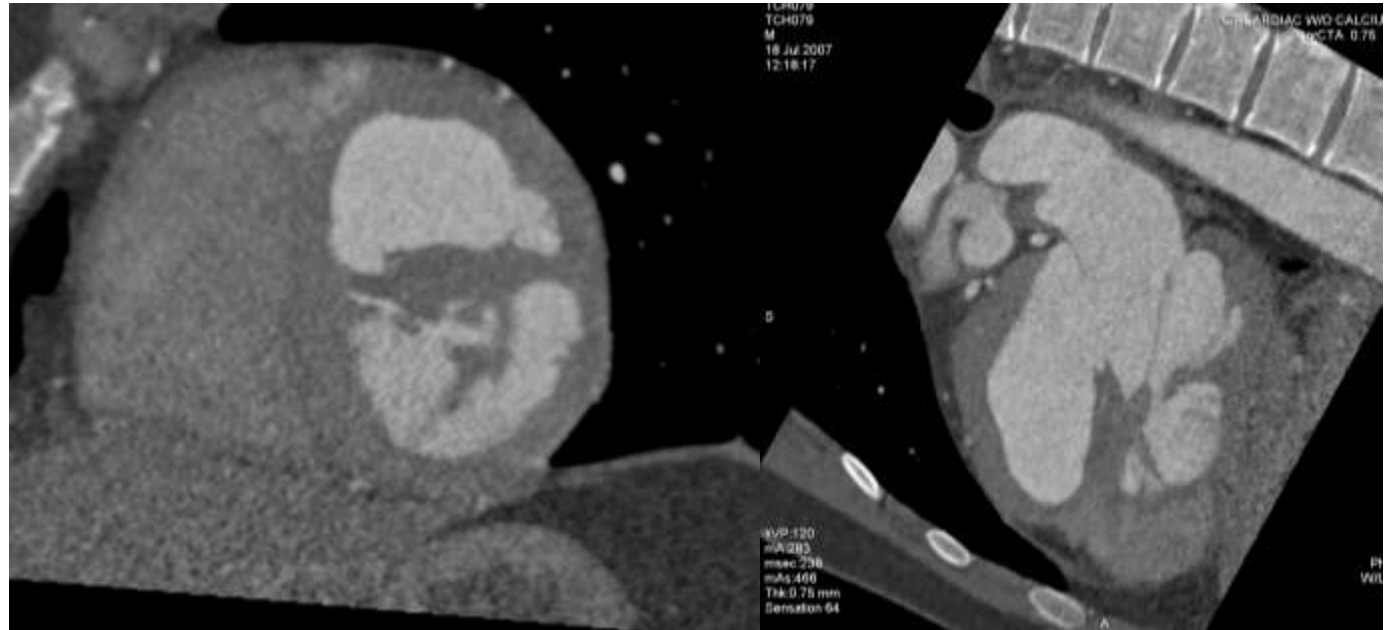


# CMR: HASTE, trueFISP, PSIR





## Low dose Cardiac CT





Diagnosis?  
Further evaluation?  
Treatment?



# Isolated Left Ventricular Non-compaction

- Standard therapy with ACE-I and beta blockers
- No coumadin: rapid clearance of contrast from trabeculations
- Progression of symptoms despite optimal therapy (NYHA IIIa)
- Dyssynchrony conformed (HARP analysis of circumferential strain)
- Biventricular ICD implanted
- NYHA I, 2 months after CRT

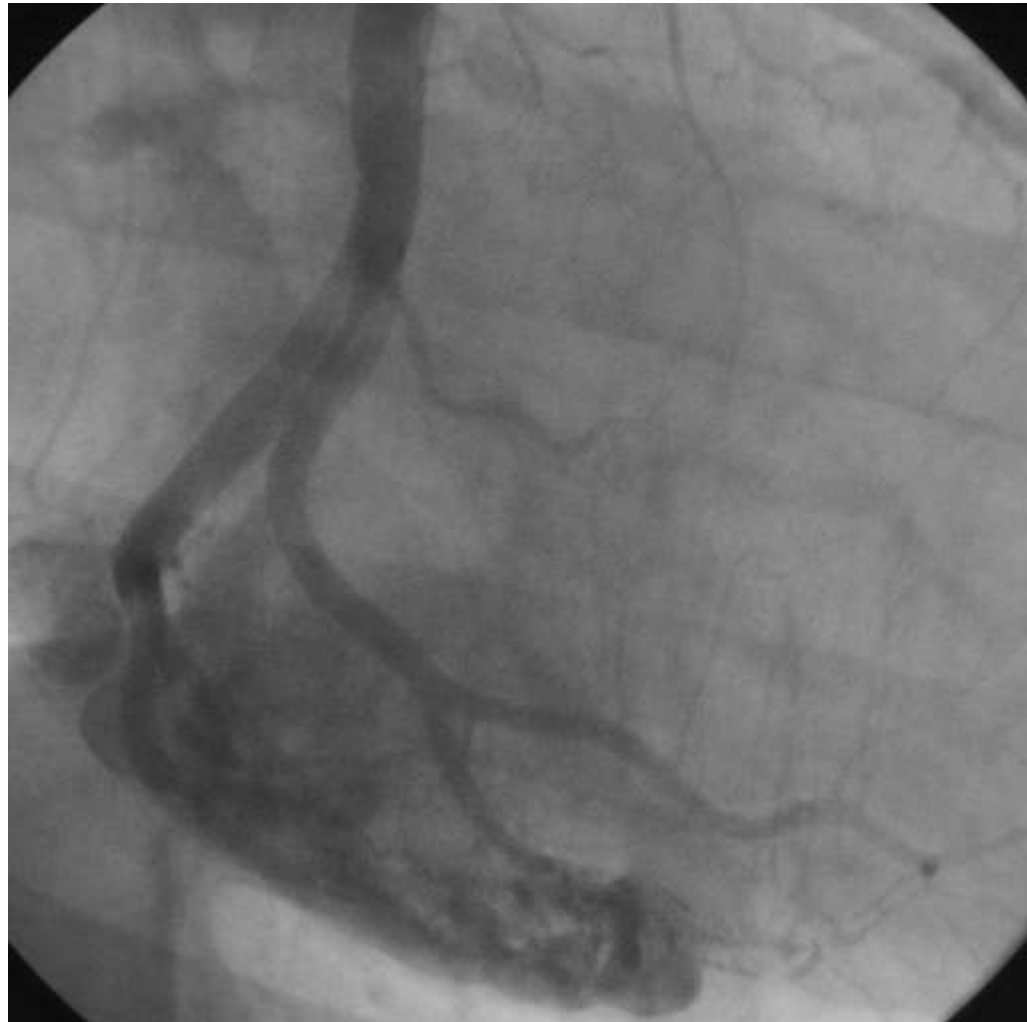

## 40 year old male with longstanding exertional chest pain

- Symptoms started in childhood with strenuous activity
- Patient avoided competitive sports
- First Coronary angiogram at age of 18, performed for abnormal GXT
- Large arteriovenous malformation was reported, without discrete connection
- Patient now presents with symptoms of CHF and new wall motion abnormality by echocardiography



# Coronary Angiogram



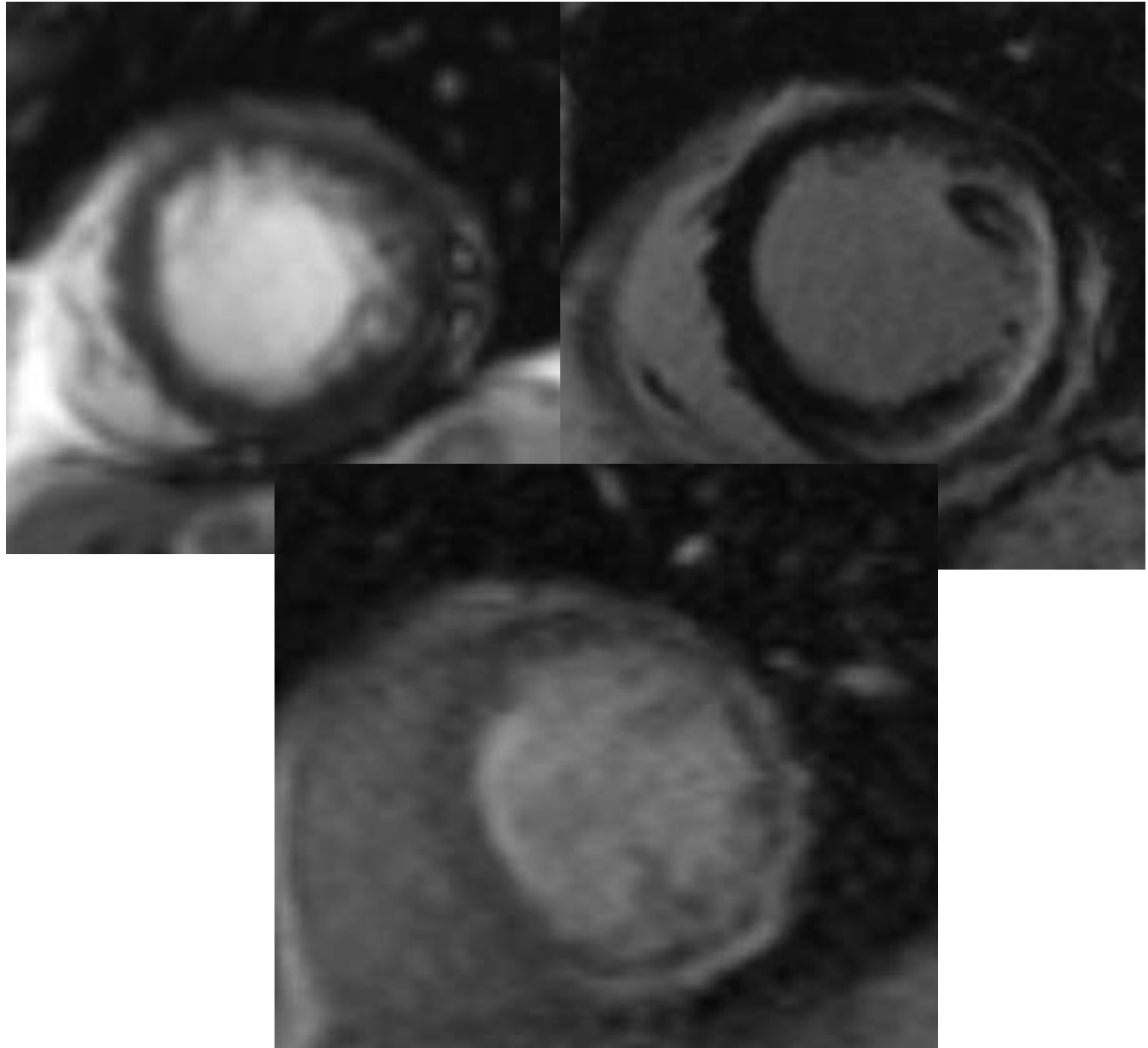


# What next?

- A: Nothing, likely infracted area supplied by AV malformation
- B: CMR to assess viability
- C: Cardiac CT to better define nature of AVM and assess viability

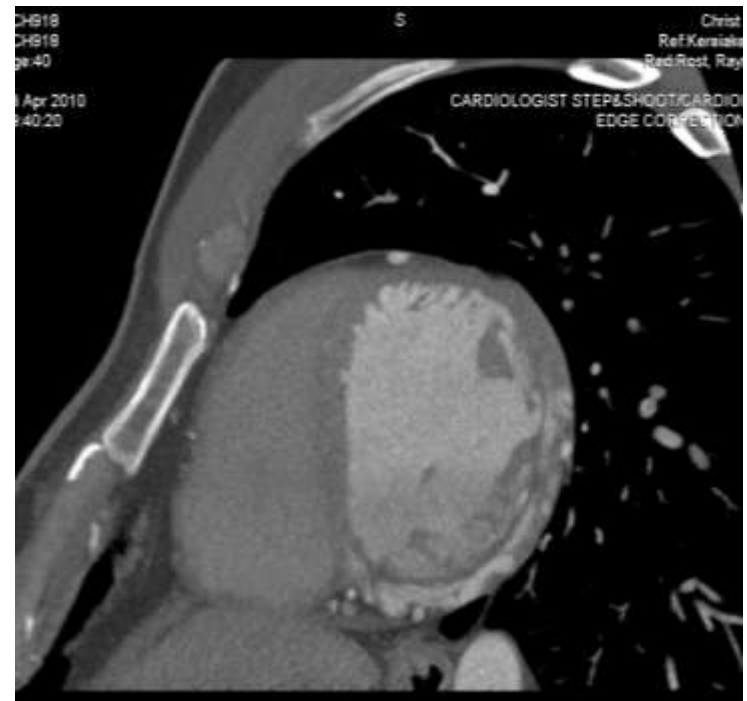
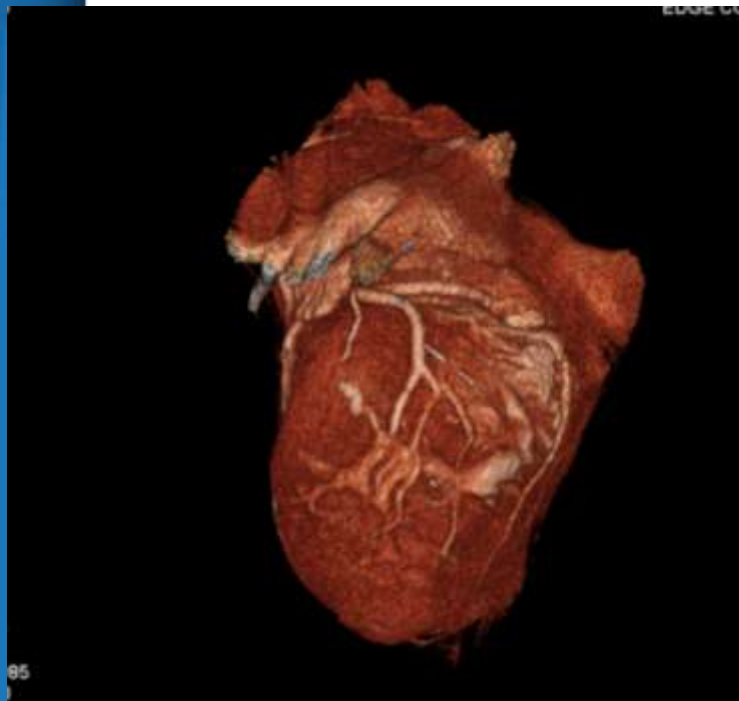
## CMR: trueFISP, TurboFLASH Late Gadolinium Enhancement and First Pass Perfusion





# Cardiac CTA



# Cavernous mural LV hemangioma

- Standard therapy for CHF
- Chest pain resolved as entire involved segment is now infarcted

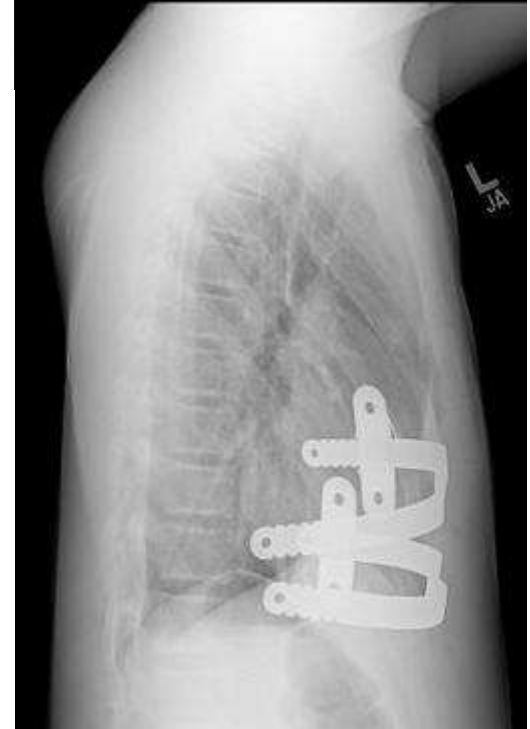
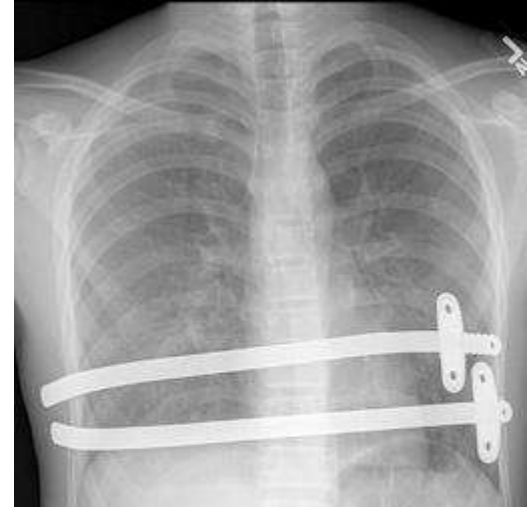
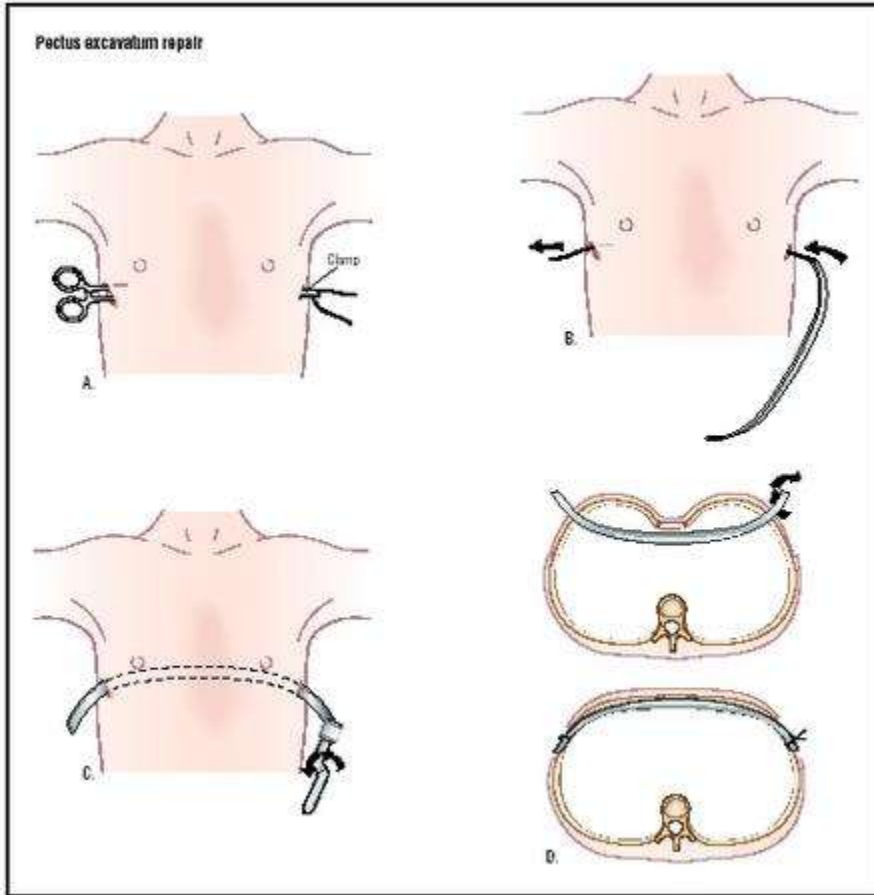


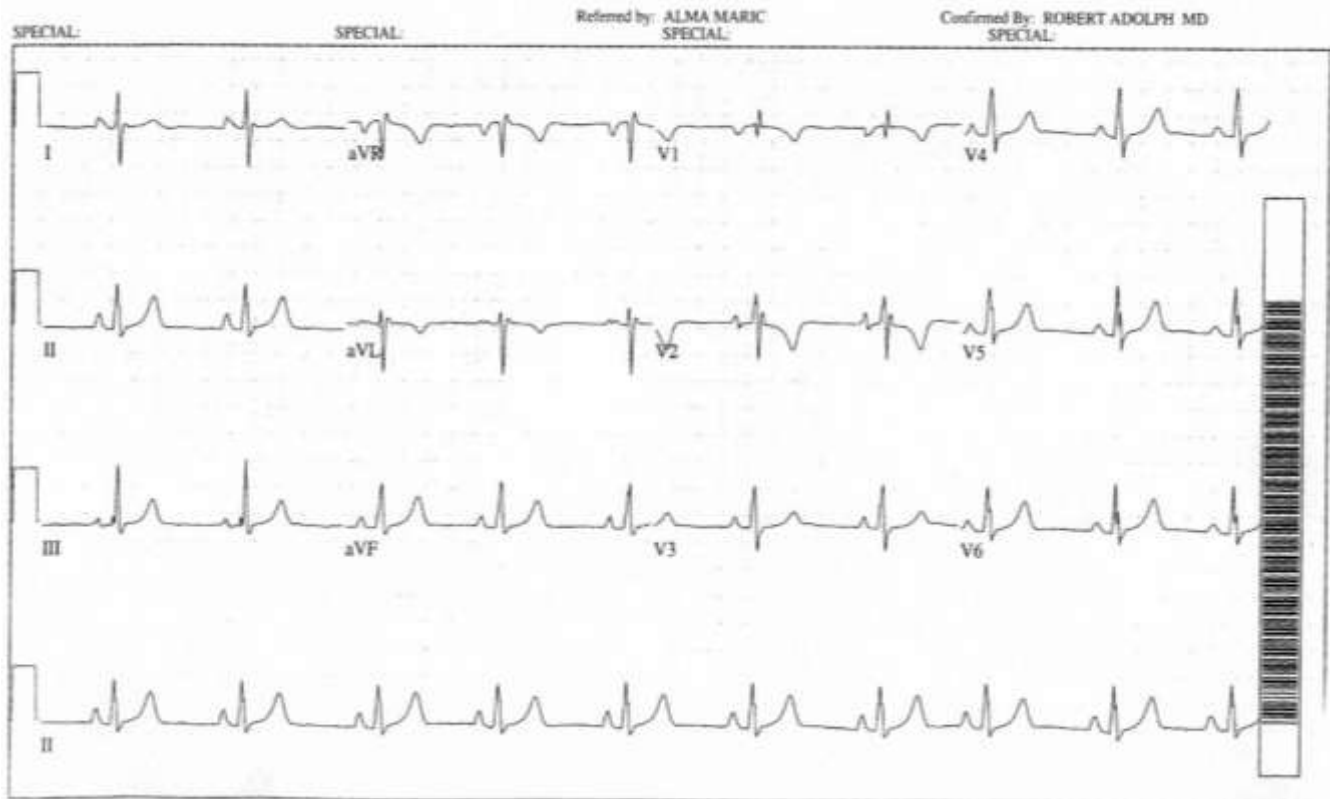


# 22 year old with syncope

- Nuss Procedure at age 14 for correction of pectus deformity
- Developed allergic reaction to sternal metal bar, which had to be removed
- Syncopal episode during a vigorous soccer training followed by seizure and no detectable pulse
- CPR initiated immediately by bystanders
- NSR and stable BP upon arrival of paramedics

# Nuss Procedure





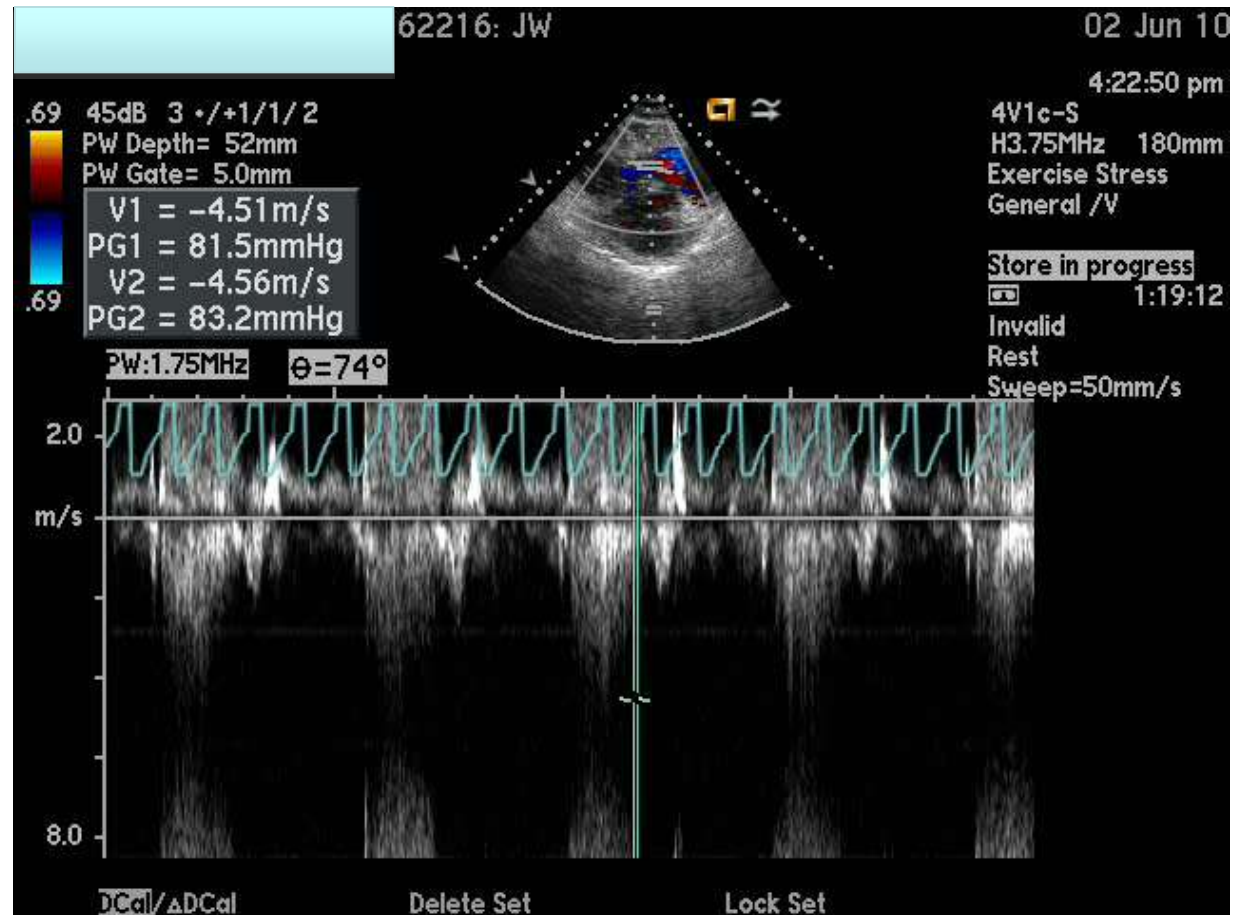


# What next?

- A: ICD implant while in hospital
- B: DC with ICD vest
- C: Further testing



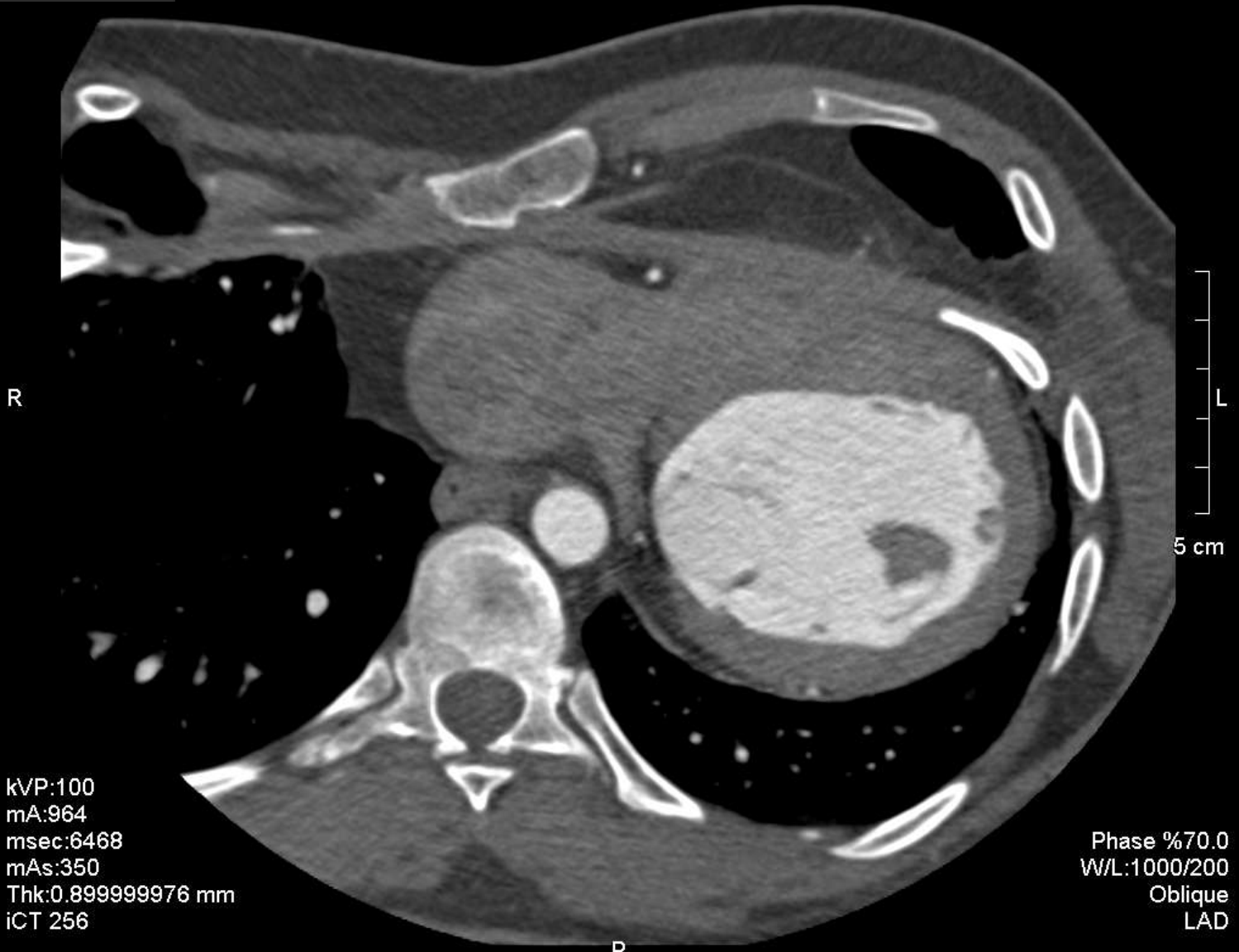
# Echocardiography





A

THE CHRIST HOSPITAL  
Ref:Mazur, Wojciech  
CT  
CARDIOLOGIST STEP&SHOOT/CARDIOLOGIST  
70% EC, 70.0%



kVP:100  
mA:964  
msec:6468  
mAs:350  
Thk:0.899999976 mm  
iCT 256

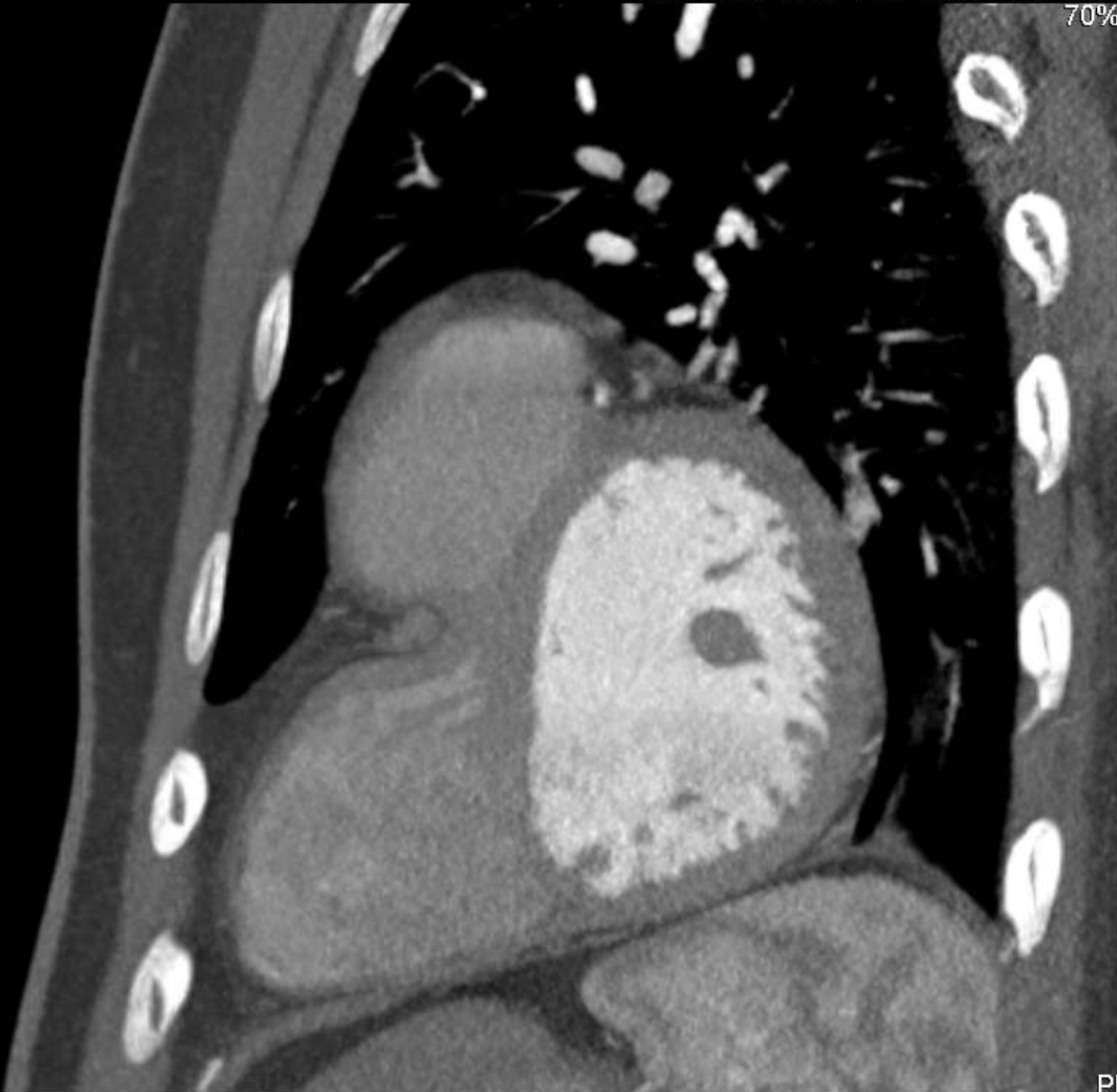Phase %70.0  
W/L:1000/200  
Oblique  
LAD



S

THE CHRIST HOSPITAL  
Ref: Mazur, Wojciech  
CT  
CARDIOLOGIST STEP&SHOOT/CARDIOLOGIST  
70% EC, 70.0%

A



P  
5 cm

kVP:100  
mA:964  
msec:6468  
mAs:350  
Thk:0.899999976 mm  
iCT 256

Phase %70.0  
W/L:1000/200  
Oblique 3.90mm MIP  
LAD

I



## Diagnosis: Extrinsic Compression of the RV by a Fibrous Band

- No ICD
- Patient underwent thoracoscopic removal of fibrous tissue
- No detectable RV intracavitary gradient with rest and stress