

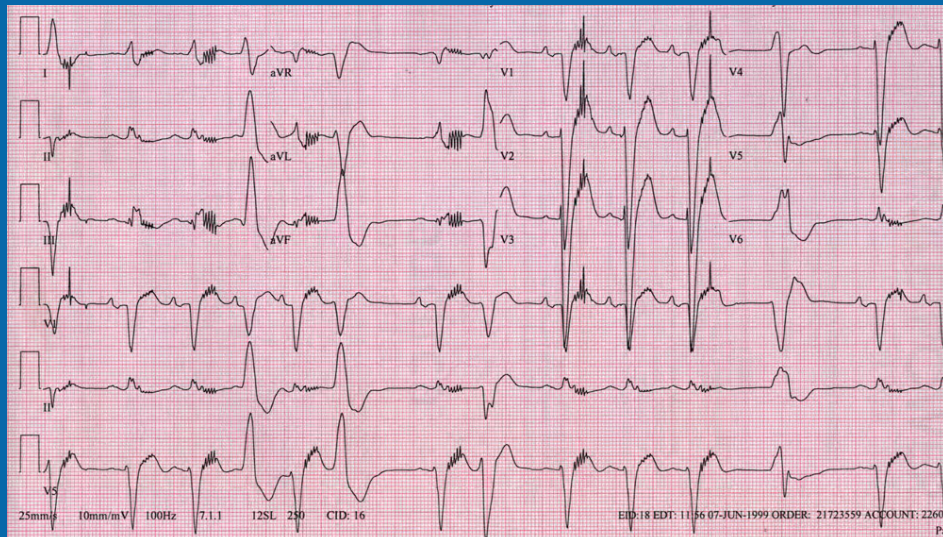


# Fascinating ECG Interpretations

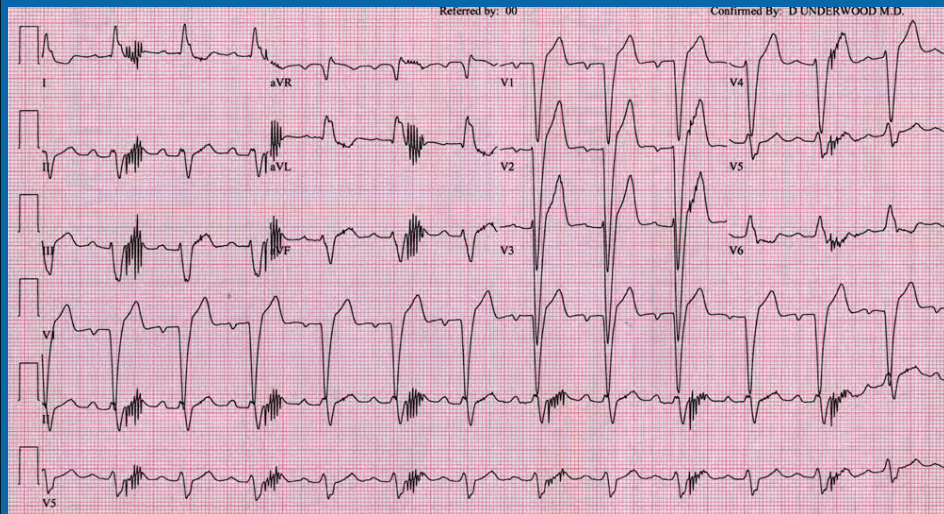
Ohio ACC 22nd Annual Meeting

**Donald Underwood MD, FACC**  
Cleveland Clinic  
Heart and Vascular Institute  
Department of Cardiovascular Medicine

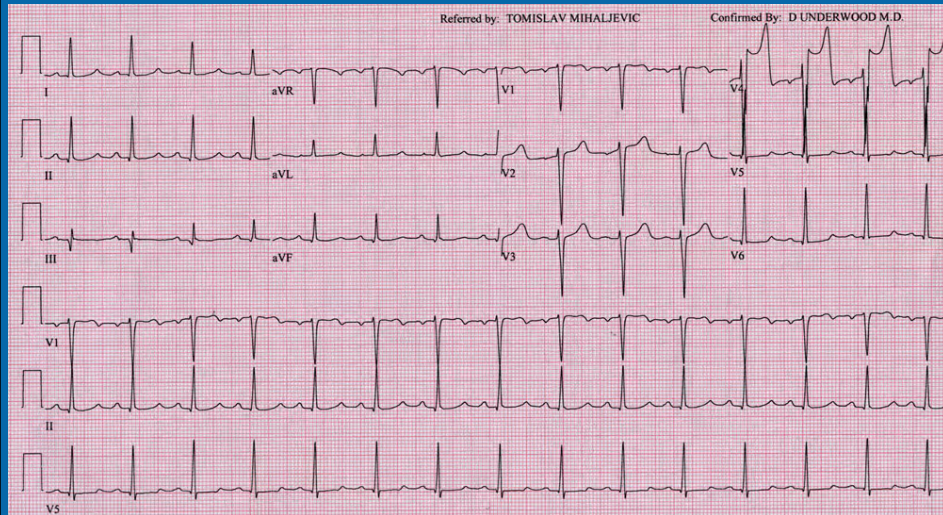
66 yo man with dilated cardiomyopathy and progressive heart failure,  
EF = 10%



Cardiomyopathy (latissimus dorsi wrap) in 1996, Survived to 2002



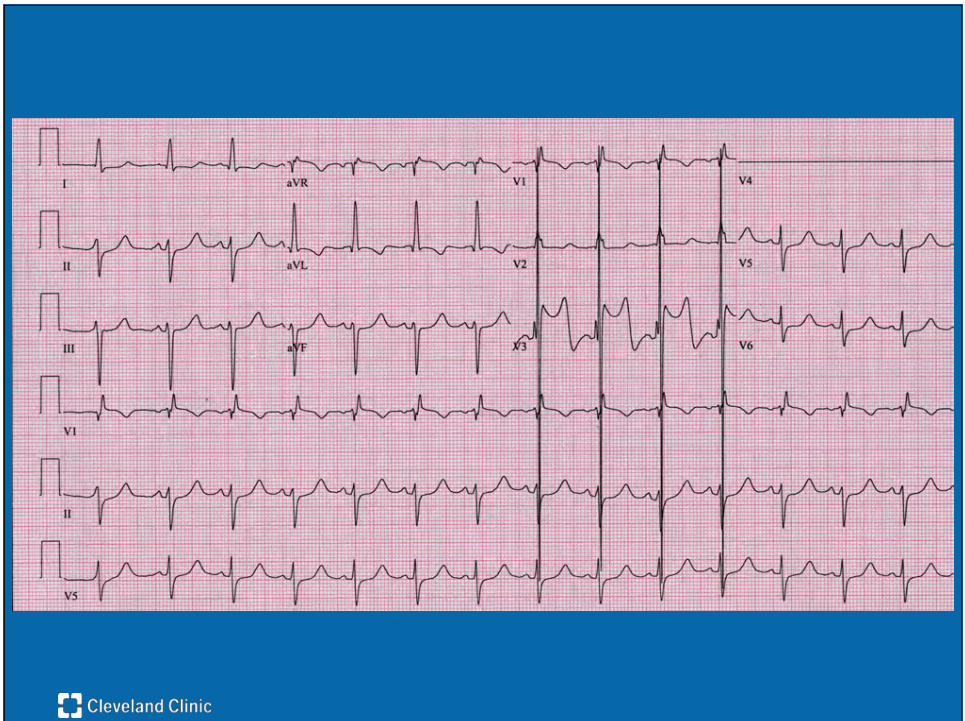
63 yo lady with severe AS. Day one following minimally invasive AVR



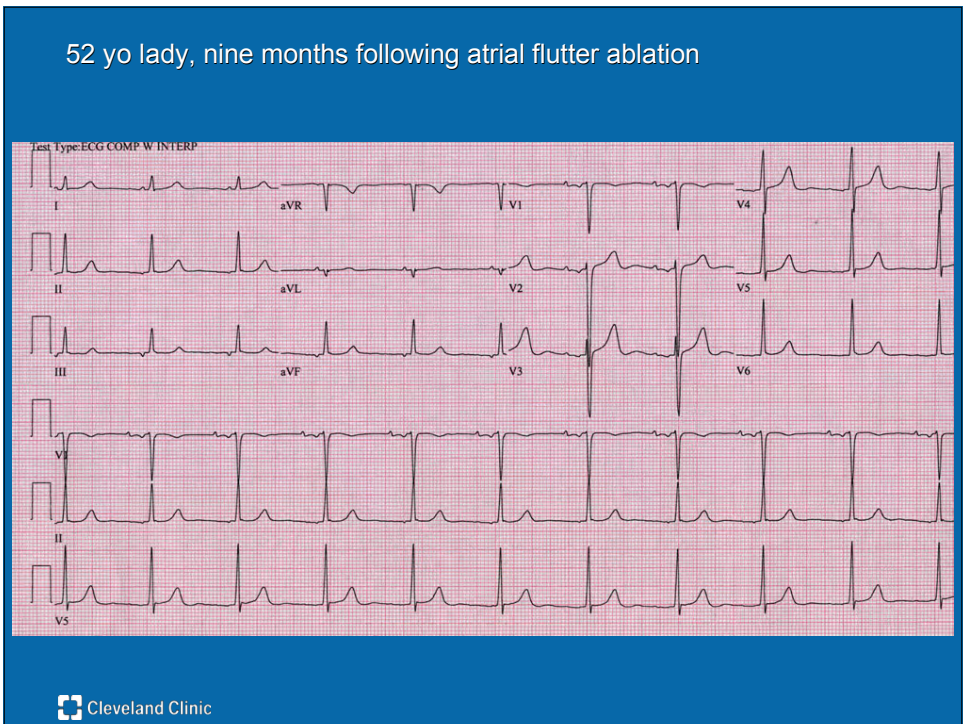
 Cleveland Clinic

Isolated epicardial recording due to “cross talk” between temporary pacing wire and the V4 precordial lead

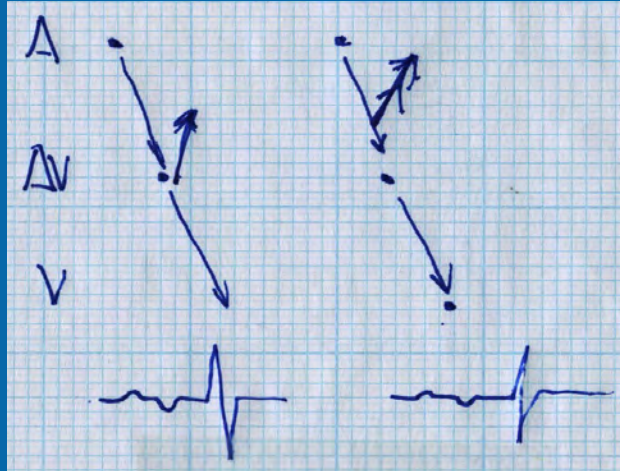
 Cleveland Clinic



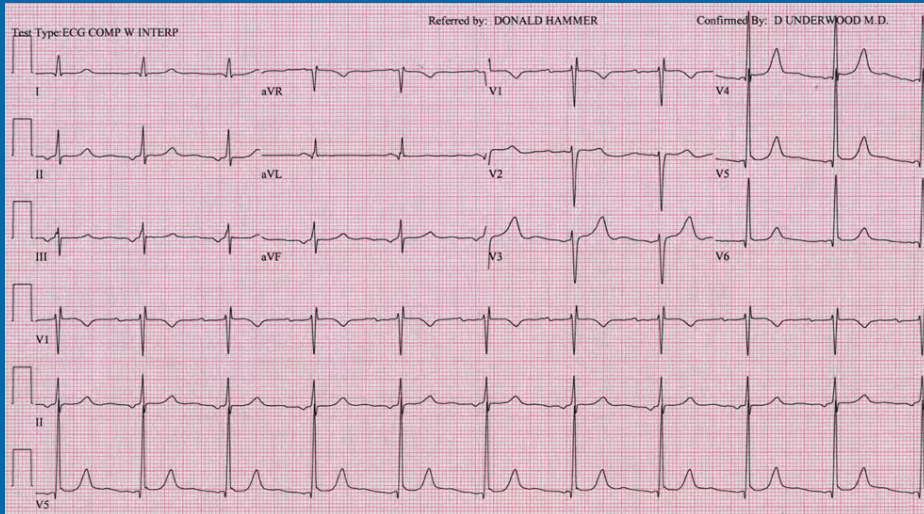
52 yo lady, nine months following atrial flutter ablation



Probable supraventricular "echo" waves-junctional or intra-atrial



Cleveland Clinic

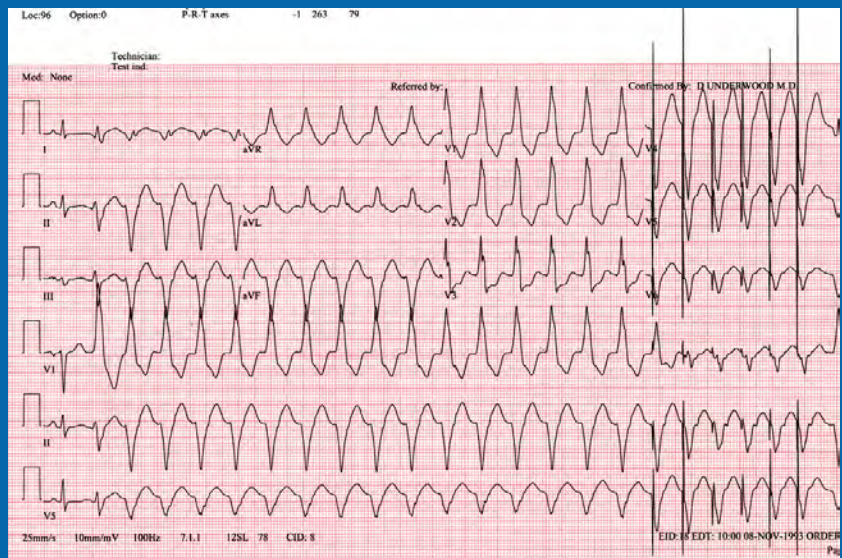


Cleveland Clinic

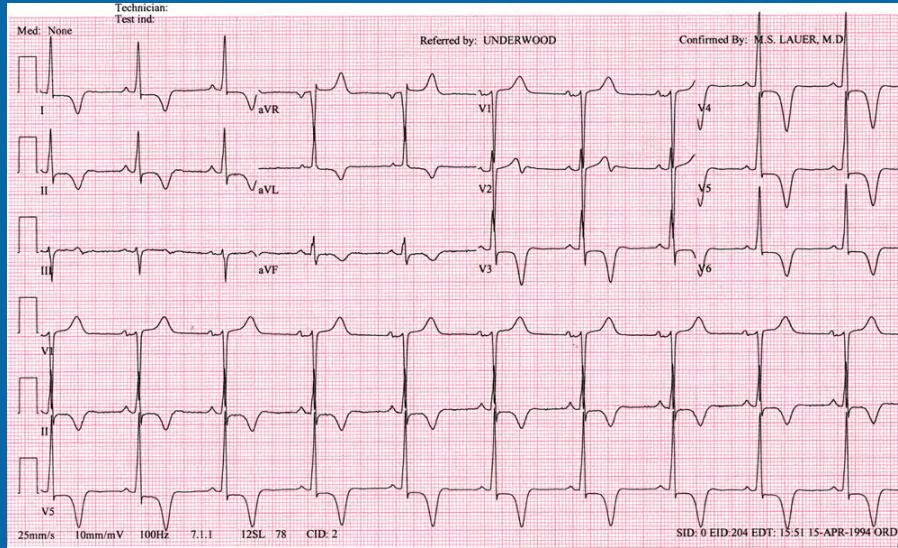
Tracings that make one wish there was a student or resident near by



66 yo man with cardiac racing

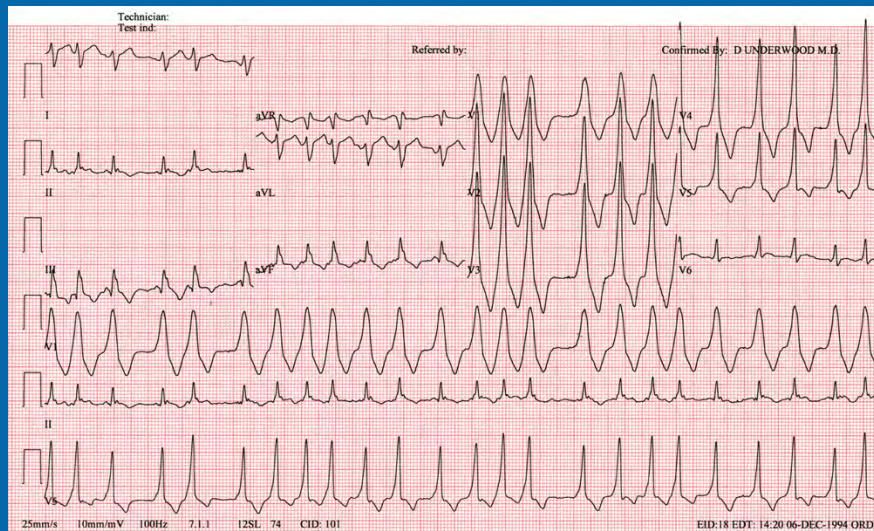


62 yo man with cardiac racing and syncope while performing in an amature orchestra-violin

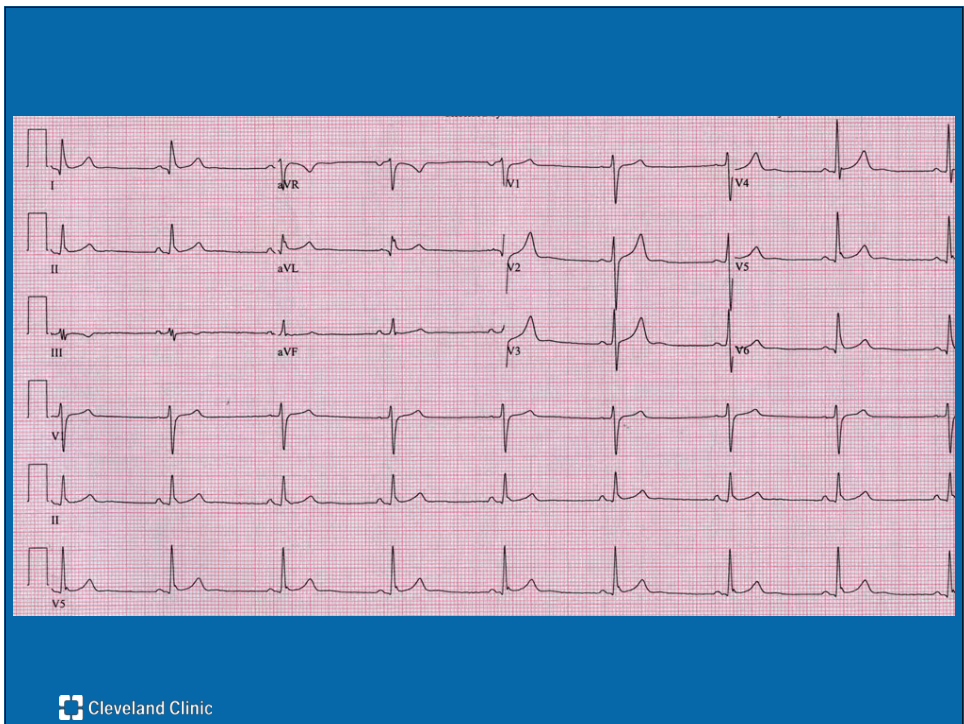
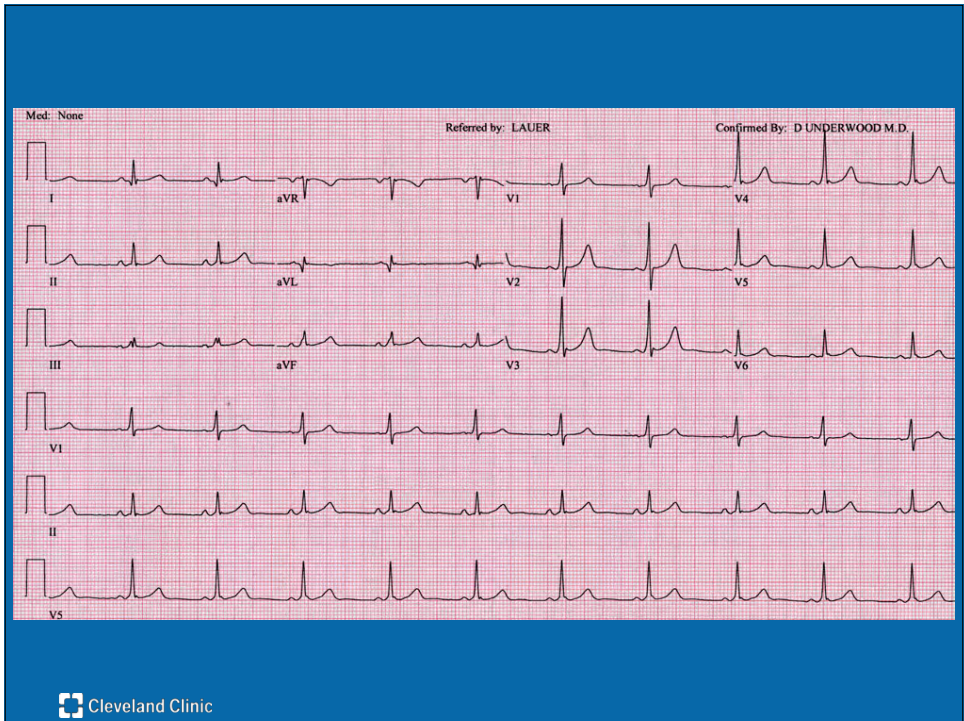


Cleveland Clinic

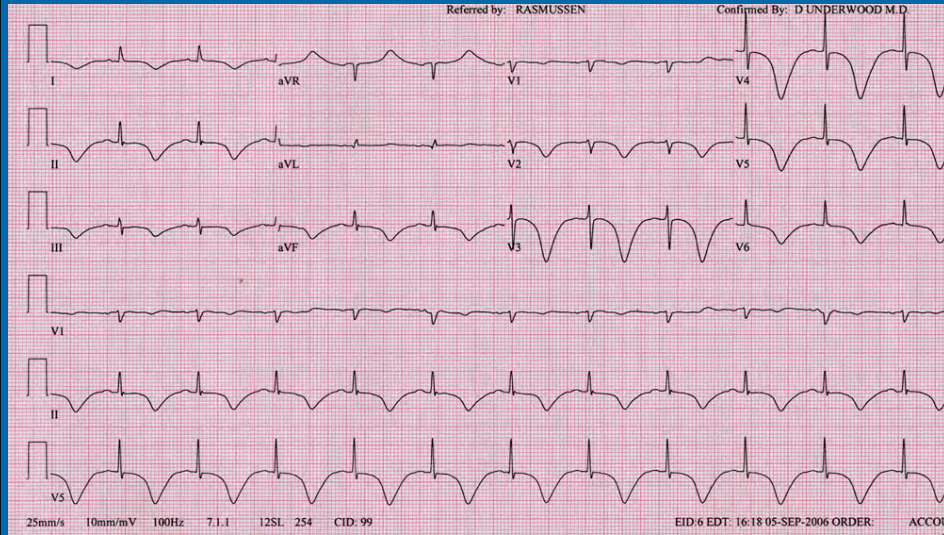
38 yo man with recurrent tachycardia and lightheadedness, no syncope



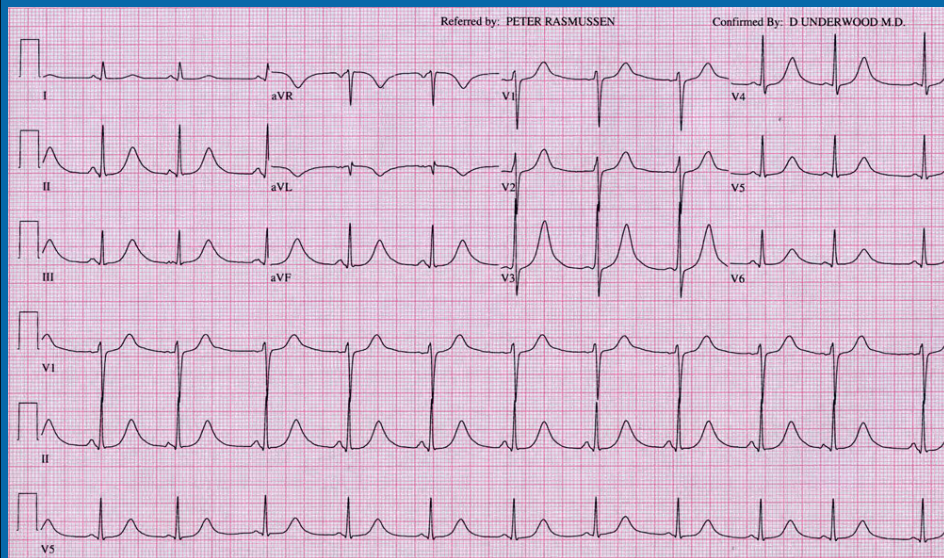
Cleveland Clinic



72 yo lady with hypertension, remote stroke on aspirin and aggrenox;  
complaining of severe headache

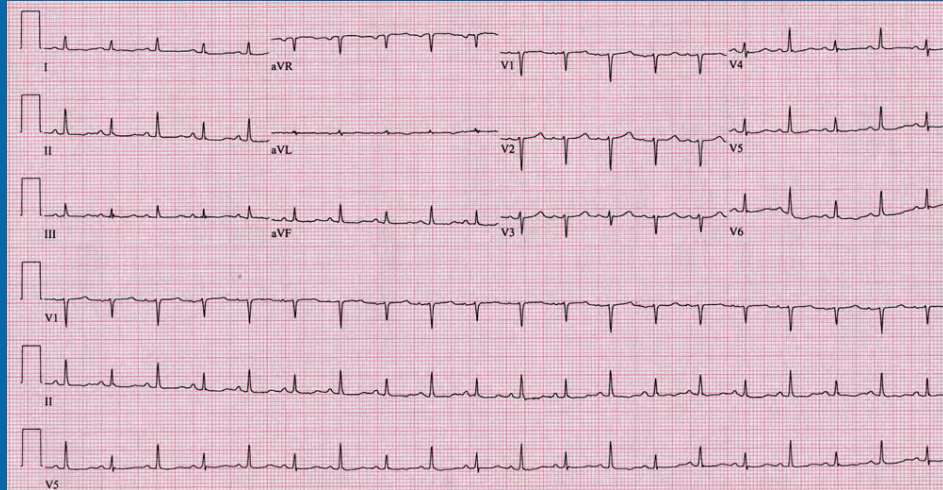


Cleveland Clinic



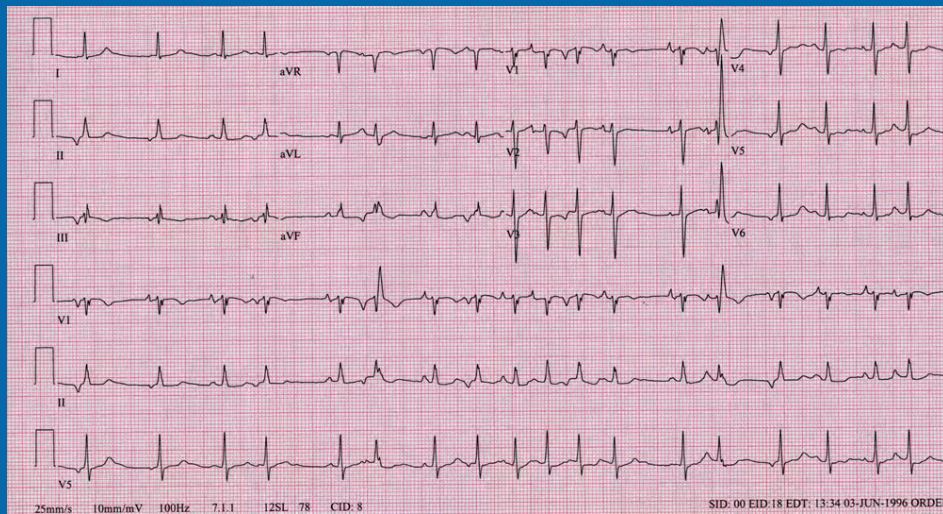
Cleveland Clinic

46 yo lady with systemic lupus, chest pain and near syncope



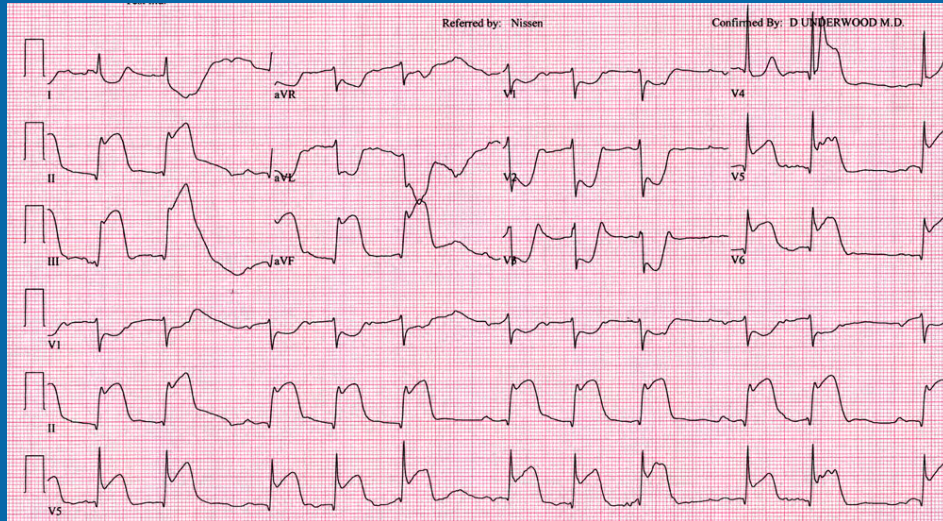
Cleveland Clinic

77 yo lady with cardiac racing and chronic shortness of breath



Cleveland Clinic

62 yo man with chest pain and sweats. Pulse is irregular.

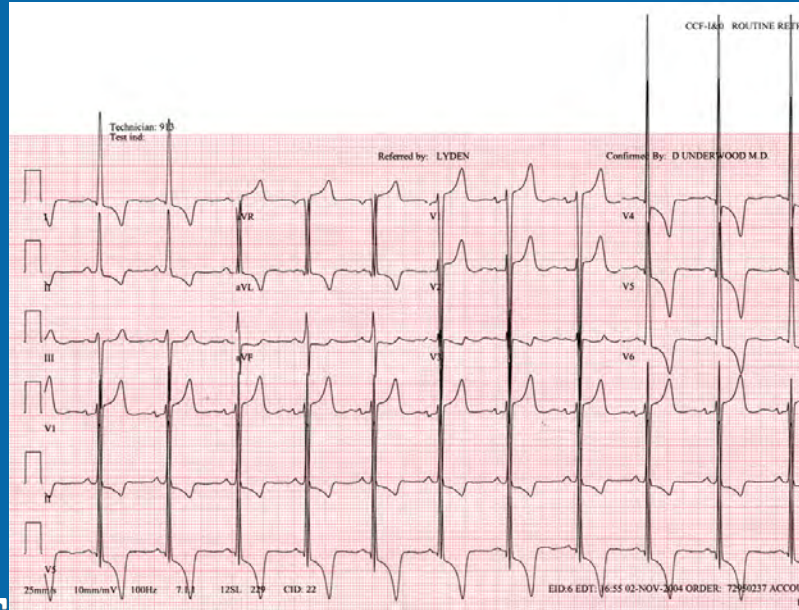


Cleveland Clinic

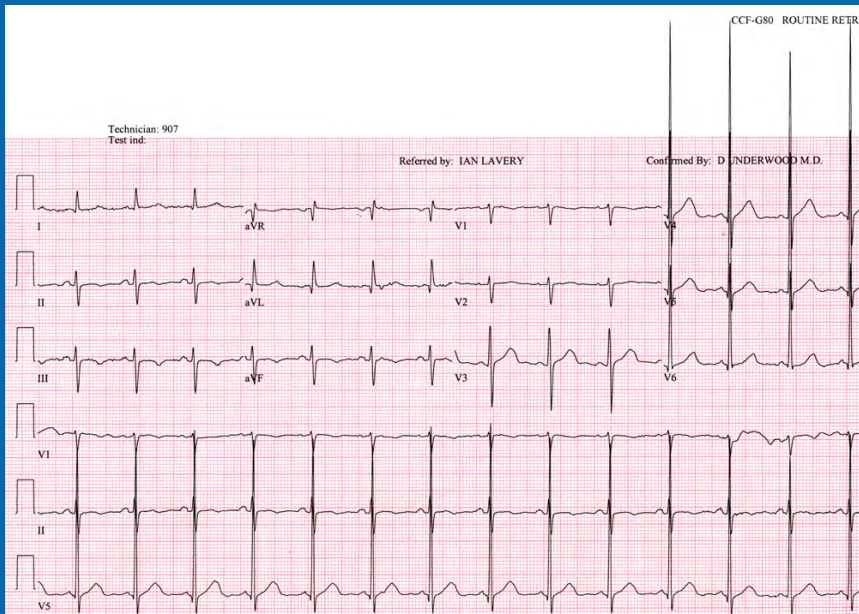
Teaching Vectors

Cleveland Clinic

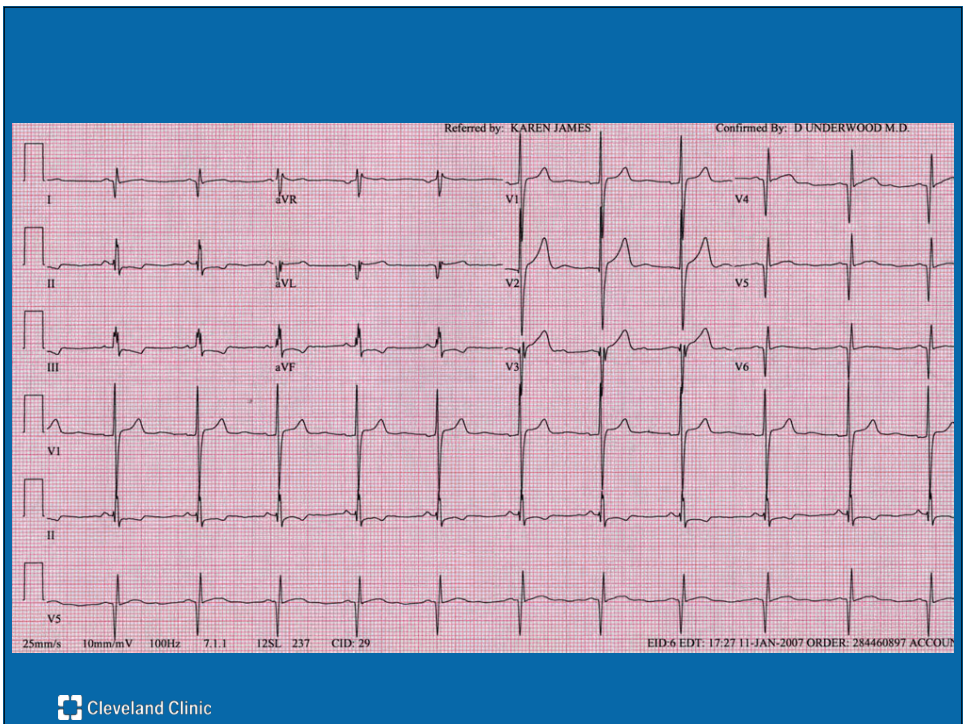
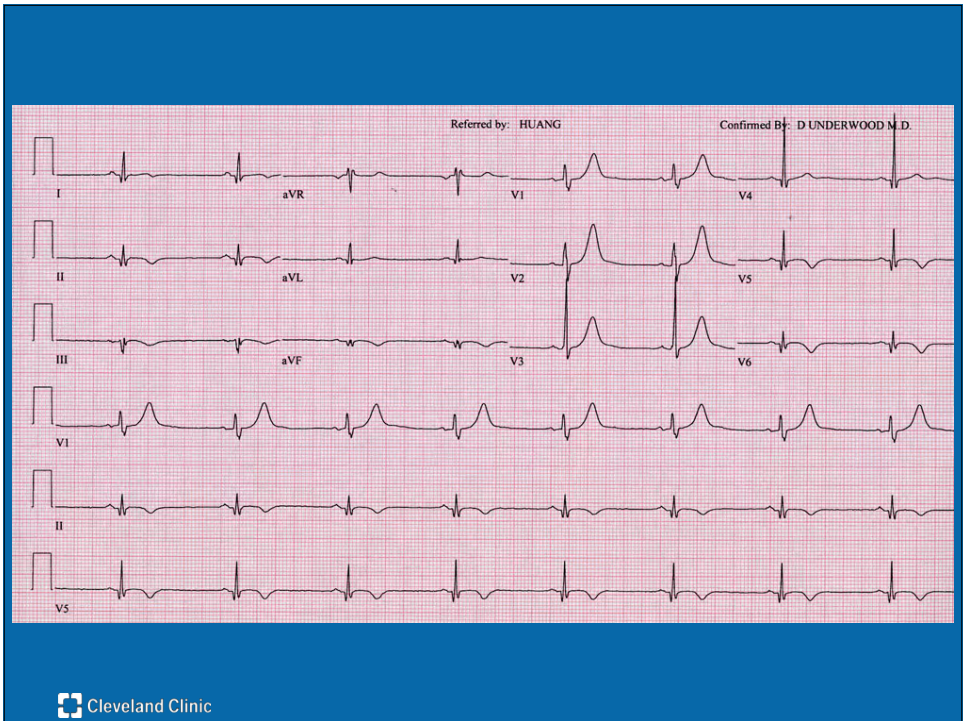
67 yo lady with long standing hypertension and occasional acute chest congestion

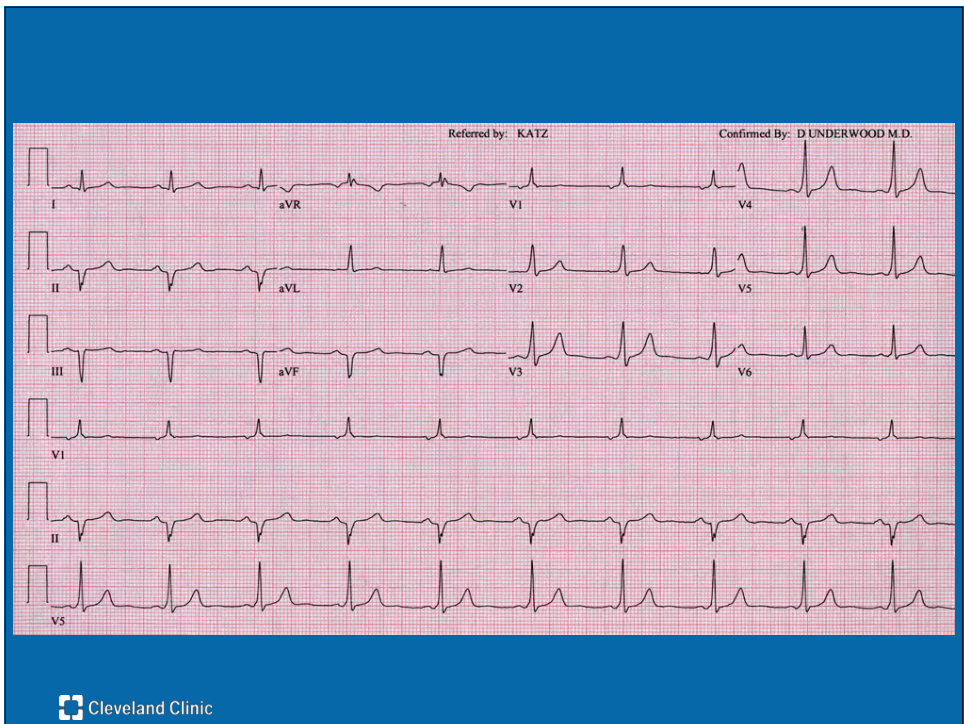
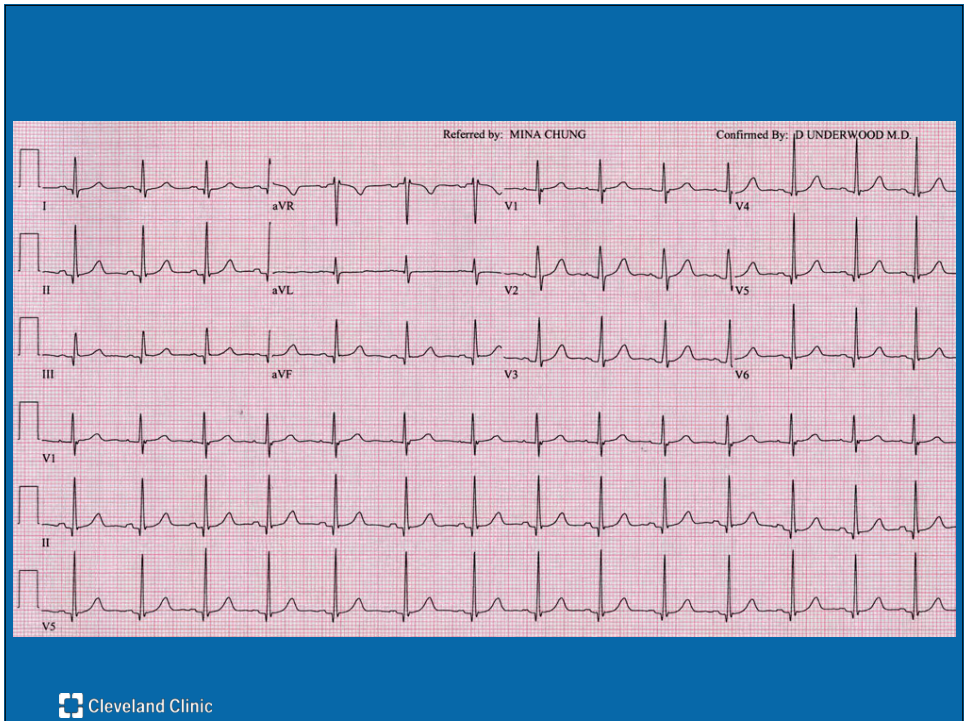


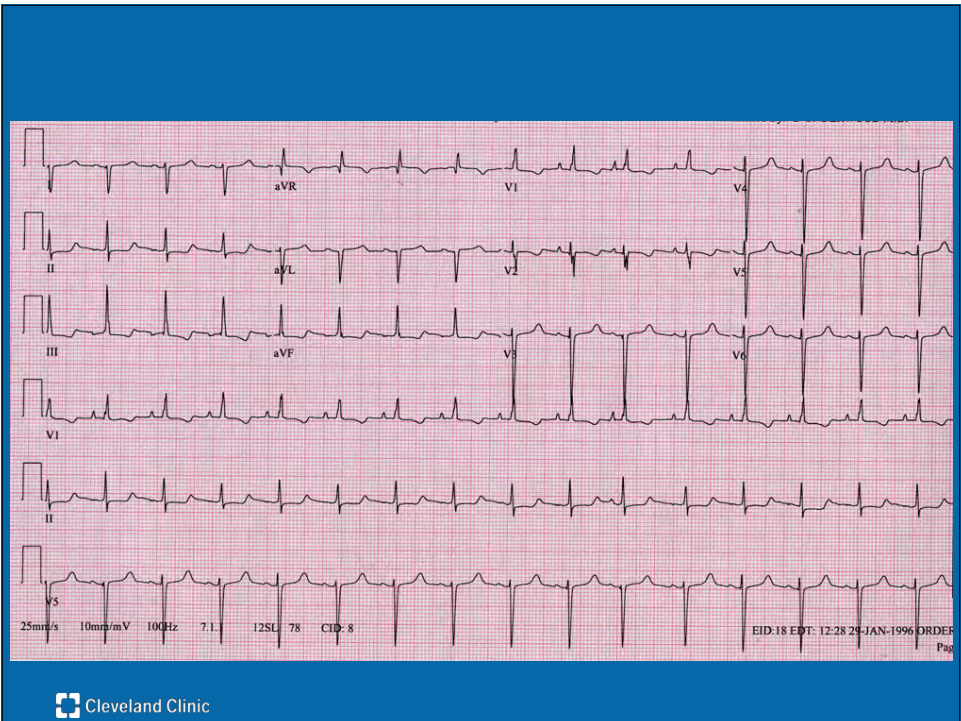
Cleveland Clinic



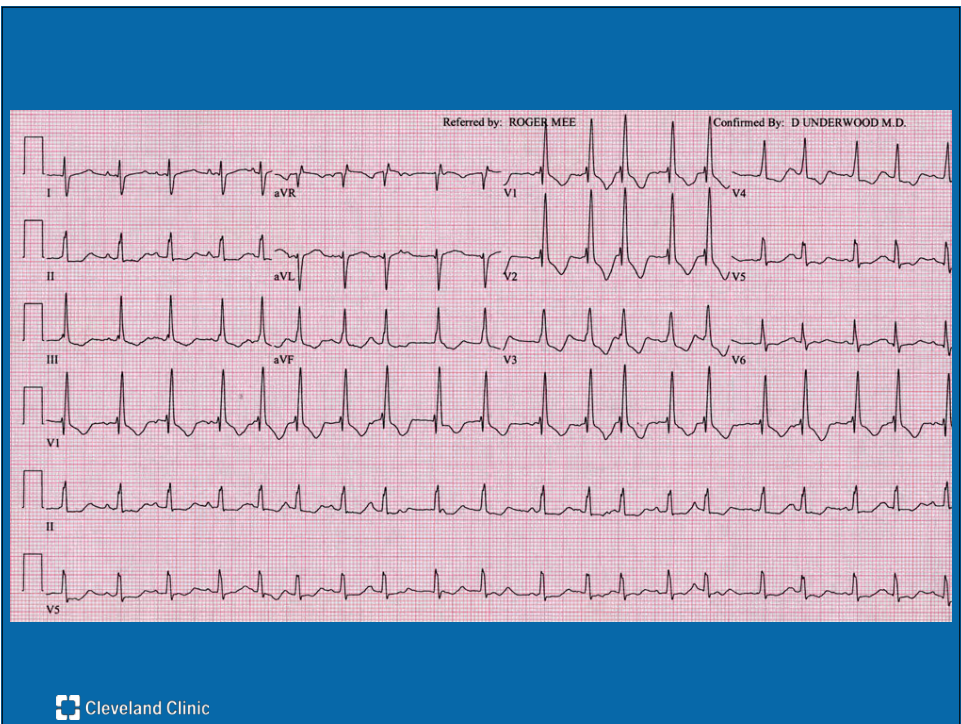
Cleveland Clinic



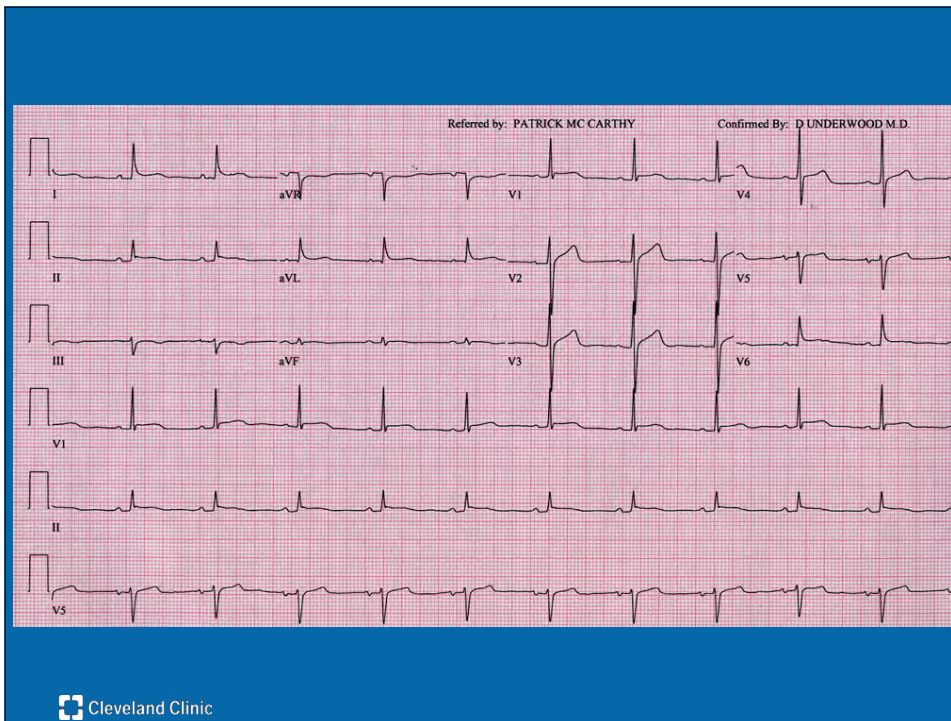




Cleveland Clinic



Cleveland Clinic



## Increase Anterior Vectors

- Inferoposterior and lateral infarct
- Becker's muscular dystrophy
- Normal young woman-early transition or counter clockwise rotation
- Pre-excitation
- Right ventricular hypertrophy pressure
- Right ventricular hypertrophy volume
- Errors

## Secondary Repolarization

